

Pneumothorax, Pneumomediastinum, and Subcutaneous Emphysema as Complications of COVID-19 Infection: A Case Series

Narges Tamaskani, Mahmoud Khandashpoor, Somayeh Livani

Clinical Research Development Unit (CRDU), Sayad Shirazi Hospital, Golestan University of Medical Sciences, Gorgan, Iran.

Received: 9 June 2020

Accepted: 6 January 2021

Correspondence to: Livani S

Address: Sayad Shirazi Hospital, Golestan

University of Medical Sciences, Gorgan, Iran

Email address: dr_slivani@yahoo.com

The novel coronavirus infection is a global health concern in 2020. Computerized tomography (CT) scan has an important role in diagnosis and follow-up with the course of the disease. The most common radiologic findings in patients are bilateral peripheral patchy ground-glass opacities and consolidations. Although in a few cases, as we reported, we encountered some rare manifestations such as pneumothorax, pneumomediastinum, and subcutaneous emphysema, which imply distinct concerns about the management and outcome of the disease. Pulmonary interstitial emphysema develops due to an increase in alveolar pressure or because of alveolar rupture, secondary to alveolar membrane damage by the virus and proceed to such a complication. Therefore, it is crucial to be aware of the complications of novel coronavirus infection in the deterioration of the disease.

Key words: COVID-19; Pneumomediastinum; Pneumothorax; Subcutaneous emphysema

INTRODUCTION

The pandemic of coronavirus disease-2019 (COVID-19) was soon declared by World Health Organization (WHO) after the initial reports in Wuhan, China, (1). COVID-19 presents with several different clinical and para-clinical features. However, the pattern and progression of the disease as well as its distinct features yet remain to be discovered.

Computerized tomography (CT) scan imaging has been used to help identify the pattern of lung involvement in suspected or confirmed cases of COVID-19 (2). Focal, multifocal or peripheral, ground-glass opacities are seen in 50% to 75% of patients in both lungs during the early phase of COVID-19 infection. Crazy paving pattern and consolidation have been reported as the dominant CT findings during the disease progresses, peaking around 9–13 days after the onset of infection, and then slowly clear

after about one month. However, there may be some sequels in different reports (2–4).

There are some uncommon presentations of COVID-19 infection in severe cases like pneumothorax, pneumomediastinum, and subcutaneous emphysema. To date, few cases of the complications of severe COVID-19 pneumonia have been reported. Here, we reviewed some cases of COVID-19 pneumonia superimposed by pneumothorax, pneumomediastinum, and subcutaneous emphysema and discussed their possible underlying mechanism.

CASE SUMMARIES

Case 1

A 55-year-old male, healthcare worker from Gorgan City, Golestan Province, in north-east of Iran, was admitted to our academic hospital with fever (38°C),

cough, and mild myalgia. He had no history of any underlying disease. Laboratory tests showed positive C-reactive protein (CRP) and a complete blood test with a normal white blood cell (WBC) count (5700 / microL; normal range 5500-11000 / microL).

On the first day of hospital admission, a chest CT scan revealed patchy consolidation with some nodular ground glass opacity in the patient's right lower lobe (Figure 1a), and his PCR test for COVID-19 became positive. Three days after hospital admission, the patient presented with shortness of breath. A second chest CT scan showed multiple bilateral patchy consolidation and ground glass opacity with peripheral distribution (Figure 1).

The patient received antiviral and antibacterial treatments; however, his condition worsened after a week. Thus, a third CT scan was performed and showed extensive bilateral ground glass opacity and superimposed interlobular septal thickening (crazy paving) with traction bronchiectasis.

On the 20th day of admission, he was intubated because of unresponsive hypoxemia, and one day later, we observed subcutaneous emphysema. Therefore, a forth CT scan was performed and demonstrated extensive bilateral ground glass opacity, a crazy paving pattern, and consolidation in the patient's lower lobe with traction bronchiectasis and perivascular lucencies. We also observed pneumoperitoneum, pneumothorax, and pneumomediastinum. Moreover, we detected subcutaneous emphysema in face, neck, chest wall, and upper abdomen.

Unfortunately, he did not respond to medical therapies, and finally, expired two weeks later.

Case 2

A 35-year-old female with no remarkable past medical history was hospitalized with dyspnea, fever (38°C), and elevated CRP. The patient's WBC count was in a normal range (6400 / microL; normal range 5500-11000 / microL).

On the first day of hospitalization, bilateral diffuse ground glass opacity and a crazy paving pattern were predominantly detected in the lower zone, as shown in her CT scan (Figure 2).

The patient was treated for coronavirus with supportive care as well as with antiviral and antibacterial agents. However, she ultimately needed intensive care unit support due to her prolonged hypoxemia. On the 12th day of admission, a second CT scan demonstrated bilateral consolidation with traction bronchiectasis and air bronchogram in the patient's lower lobes. She also showed perivascular low-attenuating haloes. Moreover, ground glass opacity and a crazy paving pattern in the upper lobes along with pneumomediastinum were observed in the patient. The patient's general condition improved after two weeks, and she was discharged from the hospital. On a follow-up chest x-ray a month later, she showed no sign of emphysema and her general condition was good.

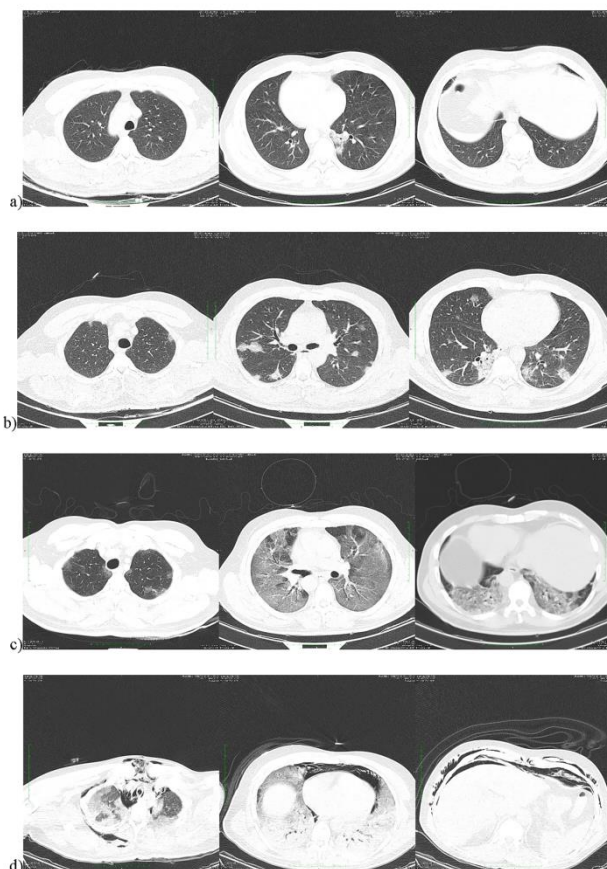


Figure 1. CT scan of 55-year-old man presented with low grade fever and myalgia

a) First CT on day 1 showed patchy GGO, **b)** CT obtained on day 3 showed multiple bilateral patchy GGO and consolidation, **c)** In his 3rd CT on day 10 crazy paving and bronchiectasis superimposed, **d)** Last CT on day 21 showed pneumoperitoneum, pneumothorax and pneumomediastinum in addition to subcutaneous emphysema.

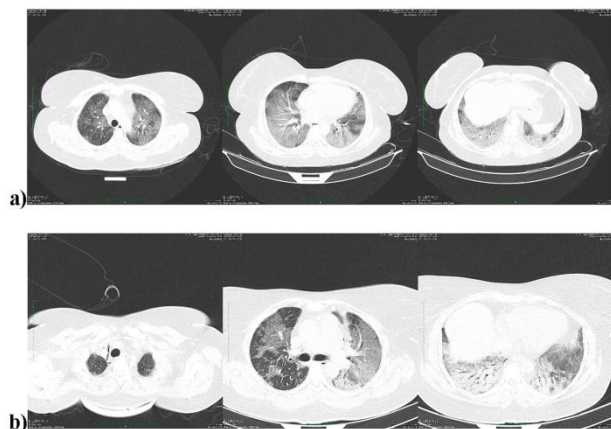


Figure 2. CT scan of 35-year-old woman hospitalized with dyspnea and fever
a) First day CT showed diffuse ground glass opacity and crazy paving pattern predominantly in lower zone, **b)** 12th day CT presented bilateral consolidation with traction bronchiectasis in addition to ground glass opacity and crazy paving pattern. Pneumomediastinum was also seen.

Case 3

A 49-year-old diabetic woman presented with myalgia and fever (37.9°C) for four days initially underwent outpatient treatment. However, she was hospitalized after the occurrence of dyspnea. The patient had a CRP, but a normal WBC count (7400 / microL; normal range 5500-11000 / microL).

A first CT scan obtained two days before admission showed multiple bilateral patchy ground glass opacity and a crazy paving pattern, especially in the patient's lower lobes with perivascular lucency. Eventually, in her second CT on the first day of hospitalization, pneumomediastinum, subcutaneous emphysema, and air into the right breast parenchyma were detected (Figure 3).

She received treatments for coronavirus including supportive care as well as antiviral and antibacterial drugs in an intensive care unit (ICU). Due to not responding to therapies, a further CT scan was performed and no pneumomediastinum and subcutaneous emphysema was detected. However, changes in consolidation and ground glass opacity were negligible. In the course of treatment, a high-dose of corticosteroid was initiated and the patient's general condition improved. In the meantime, a follow up CT scan detected multiple bilateral ground glass opacity and crazy paving with reticular opacity and a scattered sub-pleural band. One week later, her O₂ saturation became normal, the symptoms were alleviated, and she felt better and was discharged from the hospital for outpatient care.

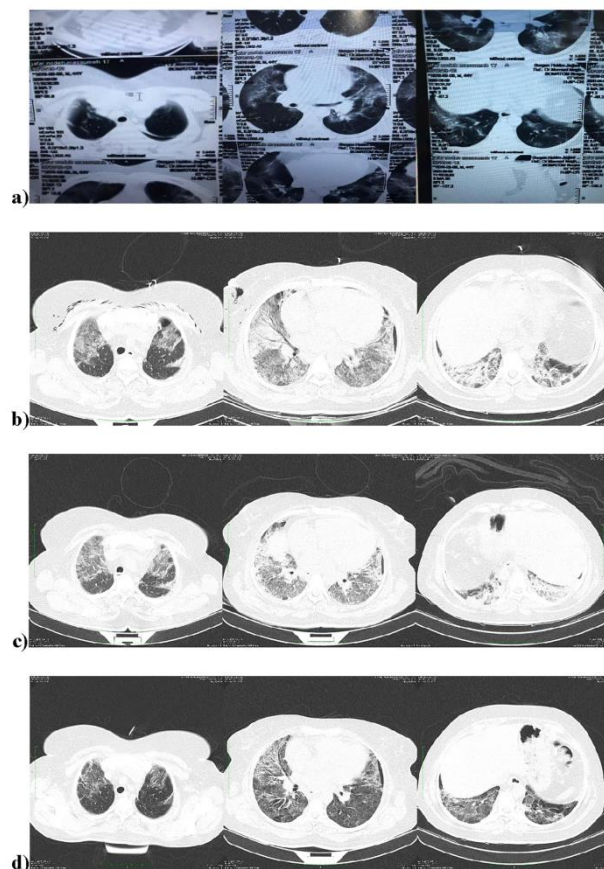


Figure 3. CT scan of 49 years old woman hospitalized with fever and dyspnea
a) Multiple bilateral patchy ground glass opacity and crazy paving pattern especially in lower lobes are seen in her first CT, **b)** Pneumomediastinum, subcutaneous emphysema and air in right breast parenchyma are added in her second CT, **c)** CT revealed no pneumomediastinum and subcutaneous emphysema in third CT, **d)** Multiple bilateral ground glass opacity and crazy paving with reticular opacity and scattered sub-pleural band in last CT

Case 4

A 50-year-old woman with past medical history of rheumatoid arthritis was hospitalized with dyspnea and fever (37.9°C). She had an increased CRP level and a WBC count lower than normal (4900 /microL; normal range 5500-11000 /microL).

On the first day of hospital stay, her CT scan showed diffused bilateral patchy ground glass opacity and an area of consolidation with bronchiectasis in her right upper lobe (Figure 4). The patient received treatments for coronavirus, but her pulse oximetry indicated hypoxemia after two days. Thus, we performed a second CT scan to detect any complication and observed widespread bilateral consolidation with a parenchymal band.

She underwent the treatment of COVID-19 in an ICU. After 20 days, her oxygen saturation improved and she was transferred to a general ward. A third CT scan showed diffuse bilateral ground glass opacity with a crazy paving pattern and consolidation with bronchiectasis. We observed multiple air cysts in the lung field. We also detected extensive pneumothorax, pneumomediastinum, and subcutaneous emphysema (Fig. 4c). Her general condition became better, and the treatment continued. A week later, a follow-up CT scan showed that pneumothorax and pneumomediastinum disappeared but diffuse bilateral patchy ground glass opacity and a crazy paving pattern with some air cysts still remained. The patient's general condition was observed to improve without any sign of hypoxemia and respiratory distress.

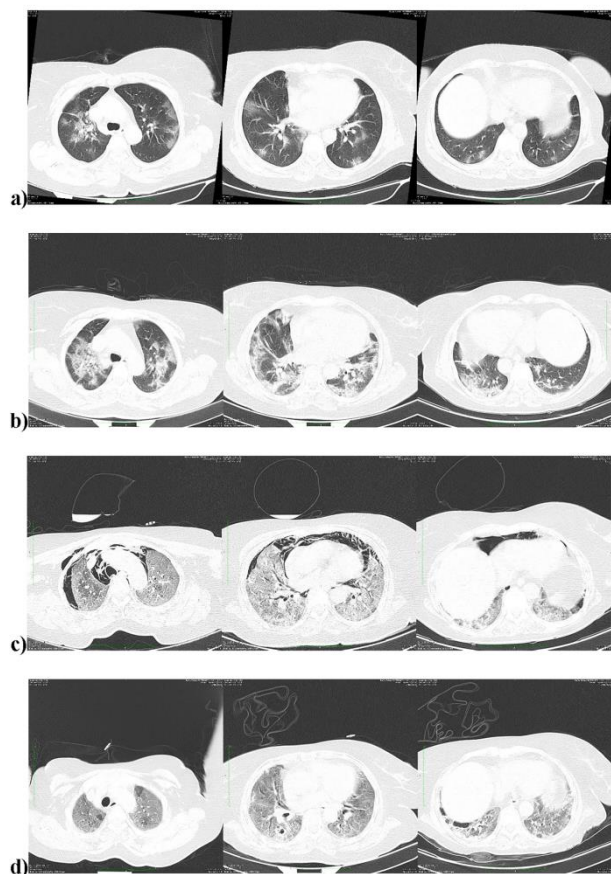


Figure 4. CT scan of a 50-year-old woman with dyspnea and fever

a) First day CT scan showed diffuse bilateral patchy ground glass opacity and an area of consolidation with bronchiectasis, **b)** Bilateral consolidation with parenchymal band were added in second CT, **c)** Here we can see extensive pneumothorax, pneumomediastinum and subcutaneous emphysema in third CT, **d)** Pneumothorax and pneumomediastinum was disappeared but there was diffuse bilateral patchy ground glass opacity and crazy paving pattern with some air cyst in last CT

DISCUSSION

Here, we reported CT findings in four patients with confirmed COVID-19 disease, developing pneumothorax, pneumomediastinum, and subcutaneous emphysema. There was no history of smoking or a previous emphysematous disease like bulla formation in our patients. However, all the cases experienced severe hypoxemia in the course of the disease.

The underlying pulmonary disease, particularly the chronic obstructive pulmonary disease, is the most common cause of secondary spontaneous pneumothorax, although pulmonary infection has also been reported as another cause (5).

Bilateral peripheral patchy ground glass opacity in lower lobes was the most common manifestation of COVID-19 in our patients. One of the patients died of COVID-19 disease, two were discharged from the hospital with good health conditions, and one is still hospitalized with the use of an O₂ nasal mask.

The most significant clinical manifestations of novel coronavirus infection, especially in cases with severe hypoxemia, are extensive pulmonary consolidation, crazy paving patterns, bronchiectasis, parenchymal distortion, and vascular dilation. Moreover, pneumothorax and pneumomediastinum have been reported in rare cases (6, 7).

Pulmonary interstitial emphysema (PIE) refers to the abnormal location of gas within PIE along bronchovascular bundles as lymphangitic patterns. PIE typically occurs in premature infants with respiratory distress syndrome, and it has been observed infrequently in adult patients. Most reports in adults were secondary to mechanical ventilation. Historically, several PIE reports during the 1918 influenza epidemic were attributed to the particular necrotizing features of the virus on pulmonary tissues. The remaining adult cases with PIE have a history of trauma or asthma (8).

PIE has three types of air leakage: 1) many cases present with centrifugal air leakage, development of subpleural bubbles and gradual occurrence of pneumothorax; 2) migration of the leaked air to centripetal, that can lead to pneumomediastinum or pneumopericardium; and 3) a rare and lethal systemic air embolism results in either air dissemination through lymphatic channels or alveolo-vascular fistulae into heart

chambers, arterial and or venous vessels. Reduced pulmonary complacency and high intra-alveolar pressure are risk factors for development of PIE (9).

The forced expiratory efforts of whooping cough may obstruct the return of the venous flow and cause to raise the intrapulmonary pressure. Alveolar base rupture may occur in case the pressure gradient is sufficient. Consequently, a severe coughing attack, regardless of its cause, may produce pulmonary interstitial emphysema and its sequel (10).

PIE may present as multiple thin-walled or air-filled cystic structures in CT. Gas gathering in the pulmonary interstitial space surrounding the bronchovascular bundles may lead to the line-and-dot pattern as a specific sign of persistent pulmonary interstitial emphysema. The lines are bronchovascular bundles and dots are punctuated soft-tissue densities within the cystic radiolucencies. Depending on the vessel orientation in relation to the plane of the CT image, the vessels could appear as lines or dots (11).

Except the first patient, pneumothorax, pneumomediastinum, and subcutaneous emphysema were observed in the other cases mentioned in the current study without any implementation of mechanical ventilation. It appears that these are complications of pulmonary viral infection with novel coronavirus. Thus, in case of encountering severe dyspnea and refractory hypoxemia, we highlighted pulmonary interstitial emphysema as an underlying cause of pneumothorax, pneumomediastinum, and subcutaneous emphysema in patients with COVID-19 disease. Follow-up CT studies in complicated cases can help us analyze these findings and manage outcomes.

CONCLUSION

This case study showed pneumothorax, pneumomediastinum, and subcutaneous emphysema to be rare complications of COVID-19 pneumonia that can deteriorate the patient's condition. It is therefore significant to be aware of these manifestations of coronavirus disease and consider follow-up CT.

Acknowledgment

In the memorial of our dear colleague, Dr. Abdollah Abbasi (infectious diseases specialist) who passed away

after a long fight with COVID-19, authors tend to appreciate the critical role of the health care workers.

REFERENCES

1. Lin X, Gong Z, Xiao Z, Xiong J, Fan B, Liu J. Novel Coronavirus Pneumonia Outbreak in 2019: Computed Tomographic Findings in Two Cases. *Korean J Radiol* 2020;21(3):365-8.
2. Ng MY, Lee EYP, Yang J, Yang F, Li X, Wang H, et al. Imaging Profile of the COVID-19 Infection: Radiologic Findings and Literature Review. *Radiol Cardiothorac Imaging* 2020;2(1):e200034.
3. Kanne JP, Little BP, Chung JH, Elicker BM, Ketani LH. Essentials for Radiologists on COVID-19: An Update-*Radiology* Scientific Expert Panel. *Radiology* 2020;296(2):E113-4.
4. Guan CS, Lv ZB, Yan S, Du YN, Chen H, Wei LG, et al. Imaging Features of Coronavirus disease 2019 (COVID-19): Evaluation on Thin-Section CT. *Acad Radiol* 2020;27(5):609-13.
5. Onuki T, Ueda S, Yamaoka M, Sekiya Y, Yamada H, Kawakami N, et al. Primary and Secondary Spontaneous Pneumothorax: Prevalence, Clinical Features, and In-Hospital Mortality. *Can Respir J* 2017;2017:6014967.
6. Zhou C, Gao C, Xie Y, Xu M. COVID-19 with spontaneous pneumomediastinum. *Lancet Infect Dis* 2020;20(4):510.
7. Sun R, Liu H, Wang X. Mediastinal Emphysema, Giant Bulla, and Pneumothorax Developed during the Course of COVID-19 Pneumonia. *Korean J Radiol* 2020;21(5):541-4.
8. Barcia SM, Kukreja J, Jones KD. Pulmonary interstitial emphysema in adults: a clinicopathologic study of 53 lung explants. *Am J Surg Pathol* 2014;38(3):339-45.
9. Amoedo MK, Souza LV, Souza AS, Júnior AS, Marchiori E. Pulmonary interstitial emphysema: a case report and review of the literature. *Radiologia Brasileira* 2013;46:317-9.
10. Macklin MT, Macklin CC. Malignant interstitial emphysema of the lungs and mediastinum as an important occult complication in many respiratory diseases and other conditions: an interpretation of the clinical literature in the light of laboratory experiment. *Medicine* 1944;23(4):281-358.
11. Donnelly LF, Lucaya J, Ozelame V, Frush DP, Strouse PJ, Sumner TE, et al. CT findings and temporal course of persistent pulmonary interstitial emphysema in neonates: a multiinstitutional study. *AJR Am J Roentgenol* 2003;180(4):1129-33.