

Tanaffos (2009) 8(3), 65-68

©2009 NRITLD, National Research Institute of Tuberculosis and Lung Disease, Iran

Polyserositis (Concato's Disease) Due to Granulocyte Colony Stimulating Factor Therapy for Lymphoma

Hamid Rouhi Boroujeni ¹, Parnia Rouhi Boroujeni ²

¹ Department of Pulmonary Medicine, Molecular cellular Research Center, Shahrekord University of Medical Sciences , ² Faculty of Pharmacy, Isfahan University of Medical Sciences, SHAHREKORD-IRAN.

ABSTRACT

Polyserositis is defined as general inflammation of serous membranes associated with serous effusion due to many causes. In this study, we evaluated polyserositis as a rare complication of GCSF therapy.

A 26-year-old man with a history of lymphoma was referred to our hospital complaining of dyspnea, tachycardia, tachypnea, chest pain, bilateral pleural effusion, ascites and massive pericardial effusion after 5 days of treatment with GCSF.

After 7 days of treatment with indomethacin, dexamethasone and discontinuation of GCSF, the patient improved and was referred to an oncologist for chemotherapy of lymphoma.

Based on this case report, we should consider various causes of pleural effusion in a patient with lymphoma, and use drugs with caution in such patients as they may be predisposed to dyspnea and fluid retention. (Tanaffos 2009; 8(3): 65-68)

Key words: Polyserositis, Pleural effusion, Ascites, Pericardial effusion, GCSF, Concato's disease

INTRODUCTION

Polyserositis is characterized by general inflammation of the serous membrane associated with serous effusion (1).

Concato's disease is defined as progressive malignant polyserositis with large effusions of pericardium, pleura and peritoneum (2).

Granulocyte colony-stimulating factor (GCSF) is secreted by monocytes, endothelial cells, fibroblasts and neutrophils and induces the proliferation of

myeloid progenitor cells (2). Lymphoma is the third leading cause of malignant pleural effusion.

The incidence of pleural effusion at presentation is 6% in cases with non-Hodgkin lymphoma and large cell lymphomas are more frequently associated with pleural diseases compared to small cell lymphoma. The cytology of the pleural fluid is positive almost in all cases (3).

CASE SUMMARIES:

Our patient was a 22-year-old male. He was a known case of mixed cellularity Hodgkin lymphoma (Figure1) diagnosed 10 months earlier and standard chemotherapy (ABVD regimen) treatment had been started for him. He had dyspnea, tachycardia,

Correspondence to: Rouhi Boroujeni H

Address: Molecular Cellular Research Center, Shahrekord University of Medical Science, Sharekord- Iran.

Email address: hammfer@yahoo.com

Received: 26 January 2009

Accepted: 19 April 2009

tachypnea, chest pain and respiratory distress and therefore a pulmonary consultation was requested for him.

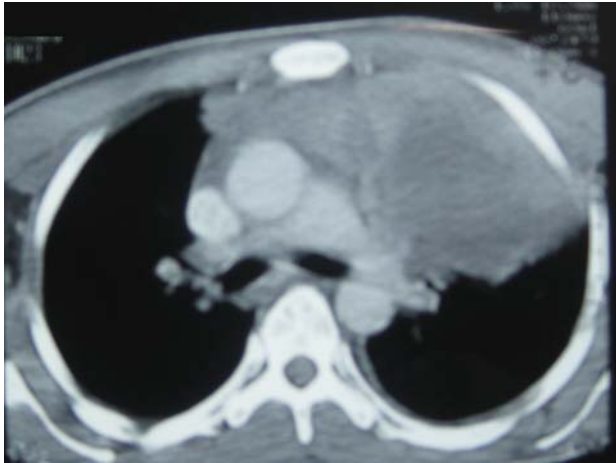


Figure 1. CT-Scan of the patient.

He received 3 courses of chemotherapy and was improved after 4 months of treatment. However, he did not show up for the follow ups and after 5 months he presented to an oncologist due to the recurrence of disease. At this time, his only complaints were cough and mild dyspnea.

Spiral CT-scan of the chest and mediastinum with contrast showed an anterior mediastinal mass without parenchymal or pleural involvement, cardiomegaly or ascites (Figure 2).

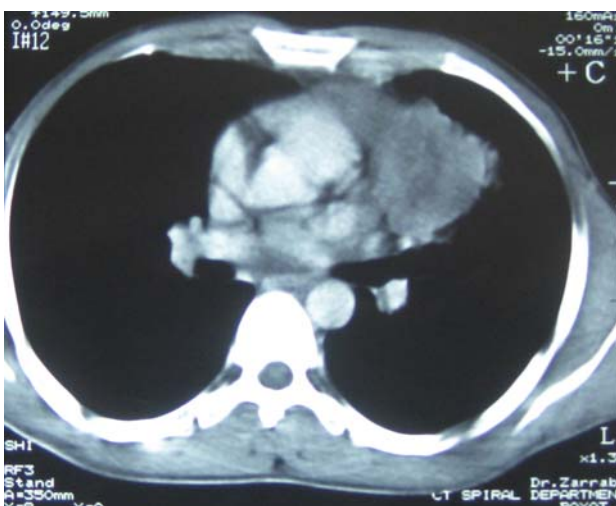


Figure 2. Spiral CT-Scan with contrast showed anterior mediastinal mass.

The patient was admitted to the oncology ward and he was treated with GCSF before chemotherapy for prophylaxis of pancytopenia which had been occurred in the previous chemotherapy. He did not receive any other medication.

After 7 days of treatment with GCSF, symptoms of respiratory distress were developed and the case was consulted with a pulmonologist. On physical examination, he had tachypnea, tachycardia and respiratory distress.

Initial examination showed an elevated jugular vein pressure (JVP) and decreased bilateral breath sounds at the lung bases associated with decreased heart sounds and ascites without peripheral edema.

CXR showed bilateral pleural effusion and cardiomegaly with consolidation in the left upper lobe due to the mediastinal mass.

Abdominal ultrasound showed ascites without hepatosplenomegaly or para-aortic lymphadenopathy (Figures 3). There was severe (massive) pericardial effusion (33mm) on echocardiography.

Right ventricle was partially collapsed but left ventricle was normal.

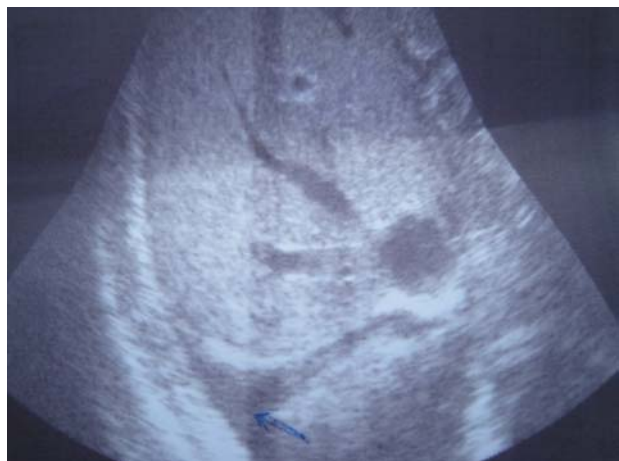

Figure 3. Abdominal ultrasound showed ascites without hepatosplenomegaly

Analysis of the pleural fluid showed the following results: WBC=6100 (with Neut=75%, Lymph=15%,

Eos=10%), RBC=290, glucose=73mg/dl, protein=1.3g/dl, LDH=937, and CEA=1.3 (normal=0-3).

Pleural fluid cytology done at 2 steps was negative.

Pleural biopsy showed no evidence of malignancy except acute inflammation.

Blood analysis showed these findings:

SGOT=60, SGPT=221, sodium=140, potassium=3.8, albumin =4.1, protein=5.9, Cr =0.9, BUN =20, LDH=864, and WBC=11000 with Poly=91%; Lymph=5%; Eos=4%

HIV Ab, HCV Ab and HBS Ag were negative.

Thyroid function tests were normal (T4=85.6; T3=105; TSH=0.68).

Tumor markers were in normal range as well {CEA=0.5 (n 0-3.5), α -FP=2.3 (n=0-5), CA19-9=9.7}.

Since the cytology was normal, pleural biopsy was negative for malignancy and GCSF had been administered for 5 days, GCSF was discontinued and the patient was treated with dexamethasone and indomethacin due to the massive pericardial effusion and followed up by daily echocardiography for 5 days because of the risk of pericardial tamponade.

After 5 days of treatment and withdrawal of GCSF, pericardial effusion improved (2 mm) and ascites and pleural effusion were resolved. After 1 month the patient had no sign or symptom of polyserositis and was referred to the oncology ward for chemotherapy of lymphoma with ABVD but without GCSF. After 6 months of follow up, the patient has not shown any sign of polyserositis.

DISCUSSION

Our patient only received GCSF on the admission day and after 5-7 days he developed severe pleural and pericardial effusion, ascites, chest pain and respiratory distress.

GCSF is a glycoprotein growth factor that promotes the proliferation of myeloid progenitor cells.

The main adverse effects of GCSF during a short-term treatment are musculoskeletal pain and dysuria. Hypersensitivity reactions have been rarely reported in patients receiving long-term treatments (5).

The most frequent adverse effects are bone and musculoskeletal pain. Other side effects include splenic enlargement, thrombocytopenia, anemia, epistaxis, headache, diarrhea and cutaneous vasculitis.

There have been reports on pulmonary infiltrates leading to respiratory failure, acute respiratory distress syndrome and anaphylactic reaction (7).

Pleural and pericardial effusion and cardiac rhythm abnormality have been rarely reported (5). However, we could not find any case of polyserositis due to GCSF in the literature.

There are several reports on exacerbation of chemotherapy-induced pulmonary toxicity in patients receiving GCSF in conjunction with bleomycin and cyclophosphamide (5,7);but our patient had received these drugs 5 months ago.

In a series of 9 patients receiving prolonged treatment with GMCSF for myelodysplasia or aplastic anemia, 4 developed hypoalbuminemia that was symptomatic in 2 of them (5,8).But our patient did not receive GMCSF and did not develop hypoalbuminemia (albumin=4.1).

GCSF should be used with caution in patients with fluid retention or heart failure as it may aggravate fluid retention and result in pulmonary edema and infiltration (5). Our patient however, had no sign or symptom of volume overload.

Acute pleuropulmonary reaction is often accompanied by eosinophilia in both blood and pleural fluids (11) and our patient had eosinophilia (about 4%, 440) and the eosinophil count of his pleural fluid was 10%.

Reactivation of various inflammatory disorders including RA and pseudogout has been reported following administration of GCSF (5, 9). However,

our patient had no evidence of collagen vascular disorders.

Thus, as described above, polyserositis in our patient was due to treatment with GCSF and probably not due to lymphoma; and discontinuation of GCSF was the basic treatment for this patient. However, due to severe pericardial effusion and partial RV and RA collapse and risk of tamponade, treatment with dexamethasone and indomethacin was started. The patient responded well to these drugs and was referred for further chemotherapy.

REFERENCES

1. Dorland W.A.N. Dorland's illustrated medical dictionary. 26th ed Philadelphia: W.B. Saunders & Co. London 1981:1051.
2. Thomas EA, Charles CJC. Cecil Essential of Medicine 5th ed. Philadelphia, Saunders, 2001: 768.
3. Light RW. Pleural diseases. 4th ed. W.B. Saunders Company, Philadelphia: 2001: 110.
4. White JM, Mufti GJ, Salisbury JR, du Vivier AW. Cutaneous manifestations of granulocyte colony-stimulating factor. *Clin Exp Dermatol* 2006; 31 (2): 206- 7.
5. Martindale: the complete drug reference, Edited by: Kathleen Parfitt 32nd ed. W.D Color Book Services. Massachusetts 1999; Vol. 1: 714- 6.
6. Matthews JH. Pulmonary toxicity of ABVD chemotherapy and G-CSF in Hodgkin's disease: possible synergy. *Lancet* 1993; 342 (8877): 988.
7. Kaczmarek RS, Mufti GJ. Hypoalbuminaemia after prolonged treatment with recombinant granulocyte macrophage colony stimulating factor. *BMJ* 1990; 301 (6764): 1312- 3.
8. Vidarsson B, Geirsson AJ, Onundarson PT. Reactivation of rheumatoid arthritis and development of leukocytoclastic vasculitis in a patient receiving granulocyte colony-stimulating factor for Felty's syndrome. *Am J Med* 1995; 98 (6): 589- 91.
9. Dirix LY, Schrijvers D, Druwè P, Van den Brande J, Verhoeven D, Van Oosterom AT. Pulmonary toxicity and bleomycin. *Lancet* 1994; 344 (8914): 56.
10. Sandor V, Hassan R, Kohn E. Exacerbation of pseudogout by granulocyte colony-stimulating factor. *Ann Intern Med* 1996; 125: 781.
11. Fishman, A. P, JA Elias, JA Fishman, MA Grippi, LR Kaiser, RM Senior (eds.): Fishman's Pulmonary Diseases and Disorders. 3rd ed McGraw-Hill International Edition; Vol. 2 1998: 1422.