

Tanaffos (2010) 9(2), 69-71

©2010 NRITLD, National Research Institute of Tuberculosis and Lung Disease, Iran

A 40-Year-Old Man with Massive Hemoptysis

Pardis Ketabi Moghaddam, Nahal Mansouri, Seyed Mohsen Moosavifard, Seyed Akbar Momenzadeh, Seyed Davood Mansouri

Mycobacteriology Research Center, Department of Internal Medicine, Division of Infectious Disease and Clinical Immunology, NRITLD, Shahid Beheshti University MC, TEHRAN- IRAN.

WHAT IS YOUR DIAGNOSIS?

A 40 year-old taxi driver residing in Tehran presented with two episodes of massive hemoptysis following a 3-week period of productive cough, dyspnea on exertion, fever, night sweat, anorexia and weakness. He was a heavy smoker (40 packs per year), and an IV drug user since 5 years ago with a history of imprisonment 3 years ago. He had no history of alcohol consumption or unprotected sexual contact. His physical examination revealed poor oral hygiene, diffuse coarse crackles in lungs, edema of the lower extremities which was dominant in the left leg and no petechia, purpura or any other skin lesion. He had normal blood biochemistry, liver function tests and electrolytes. Complete blood count revealed a microcytic, hypochromic anemia with a PMN dominant leukocytosis and normal platelet count. Erythrocyte sedimentation rate was 87. PPD was non-reactive and 3 times sputum smear for acid fast bacilli was negative. Urinalysis was normal. Chest x-ray (Figure 1) and lung CT-scan (Figure 2) were performed. Transthoracic and transesophageal echocardiographies (TTE & TEE) were reported to be normal without vegetation or other abnormalities. (*Tanaffos* 2010; 9(2): 69-71)

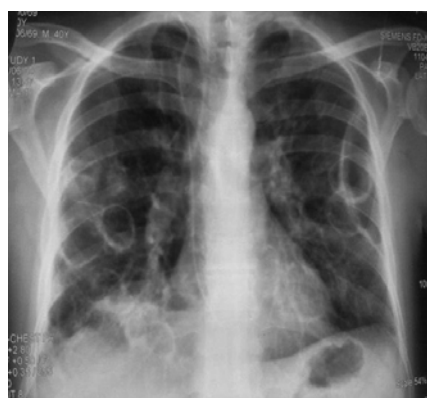

Figure 1. Chest x-ray of the patient.

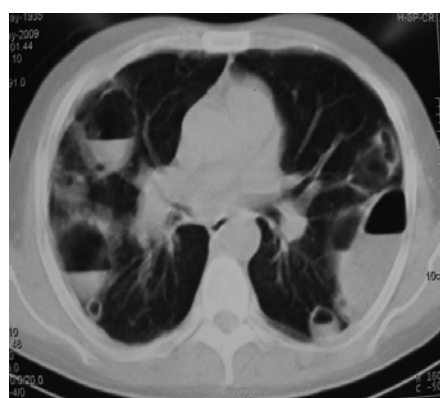

Figure 2. Lung CT-Scan of the patient.

Correspondence to: Mansouri D

Address: NRITLD, Shaheed Bahonar Ave, Darabad, TEHRAN 19569, P.O:19575/154, IRAN

Email address: dmansouree@yahoo.com

Diagnosis: Multiple septic pulmonary emboli due to septic thrombophlebitis

Further laboratory tests showed normal titers of C-ANCA, P-ANCA, anti ds-DNA and ANA. His blood culture after 72 hours was negative. Plasma anti HCV Ab and plasma PCR for HCV-RNA were positive. He had positive plasma anti HIV Ab with negative plasma PCR for HIV and his absolute CD4+ T-cell count was 320. Serology for hepatitis B revealed recovery from HBV infection with high titers of anti HBs and anti HBc antibodies. VDRL was negative. Plasma PCR for CMV and EBV was negative. A color Doppler sonography of lower extremities revealed insufficient venous flow and thrombosis in the left popliteal vein representative of the deep vein thrombosis (DVT) of the left popliteal vein. Considering the documented DVT in left popliteal vein which could be originated from multiple injections in this area and after refuting other probable diagnoses such as right-sided endocarditis and vasculitis; the diagnosis of multiple pulmonary septic emboli due to septic thrombophlebitis was confirmed. Typical pearl-shaped pattern of multiple pulmonary emboli can be seen in Figure 1. The patient's condition ameliorated after a trial of vancomycin and ceftazidime for three weeks with defervescence, no recurrence of hemoptysis, respiratory improvement, a significant decrease in ESR, and resolution of cavities on CT-scan (Figure 3). Septic pulmonary embolism presents with variable and often nonspecific clinical and radiographic features. The diagnosis is usually suggested by the presence of a predisposing factor, febrile illness, and CT findings of multiple, nodular lung infiltrates peripherally, with or without cavitation. Septic pulmonary embolism has been associated with risk factors such as IV drug abuse, pelvic thrombophlebitis, suppurative processes in the head and neck and odontogenic infections (1). Increasing use of indwelling catheters and devices as well as increasing numbers of immunocompromised

patients and intravenous drug users have changed the epidemiology and clinical manifestations of septic pulmonary embolism (2).

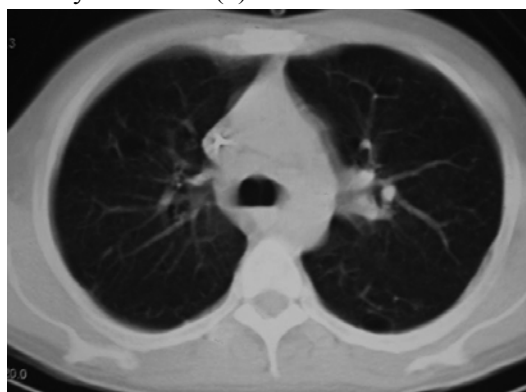


Figure 3. Resolution of cavities on CT-scan.

A high percentage of affected patients have no history of antecedent valvular damage. At the outset of their illness, patients may present with fever alone, without cardiac or other localizing findings. As a result, a high index of clinical suspicion is essential to the diagnosis. In patients with a history of intravenous drug abuse the most common source of septic pulmonary emboli is an infected tricuspid valve (3). In this case the first consideration was right-sided endocarditis and profound work up consisting of blood cultures and echocardiography was inconsistent with this diagnosis. Thus a probable diagnosis of septic emboli from other sites was investigated which revealed popliteal vein septic phlebitis despite lack of any clinical manifestation.

REFERENCES

1. Cook RJ, Ashton RW, Aughenbaugh GL, Ryu JH. Septic pulmonary embolism: presenting features and clinical course of 14 patients. *Chest* 2005; 128 (1): 162- 6.
2. Coentrão L, Oliveira J. Septic pulmonary embolism - case report. *Rev Port Pneumol* 2008; 14 (6): 881- 5.
3. Franklin D. Lowy. Staphylococcal infections in: Harrison's principles of internal medicine. 17th edition. McGraw-hill; 2009; 877.