

*Tanaffos* (2006) 5(4), 37-42

©2006 NRITLD, National Research Institute of Tuberculosis and Lung Disease, Iran

## Surgical Resection: The Mainstay of Management of Type II Pulmonary Arteriovenous Malformations

Seyed Ziaallah Haghi<sup>1</sup>, Majid Mirsadraee<sup>2</sup>, Reza Bagheri<sup>1</sup>, Ali Sadrizadeh<sup>1</sup>, Fariba Rezaee Talab<sup>3</sup>

<sup>1</sup> Department of Thoracic Surgery, Mashhad University of Medical Science and Health Services, <sup>2</sup> Department of Pulmonary Medicine, Mashhad Islamic Azad Medical University, <sup>3</sup> Department of Pulmonary Medicine, Mashhad University of Medical Sciences and Health Services, MASHHAD-IRAN.

### ABSTRACT

**Background:** Twenty percent of pulmonary arteriovenous malformations (PAVM) are type II PAVMs. This type of PAVM is characterized by less than 5 AVMs in the body and no other vascular anomalies such as AV fistulas or aneurisms. We studied seven cases of type II PAVMs in which surgical resection was the mainstay of treatment. All were free of symptoms and without relapse after the surgery.

**Materials and Methods:** During a 26-year period, 7 subjects proven to have PAVM by imaging studies were entered in this cross-sectional study. Demographic, clinical and imaging findings along with results of catheterization and angiography were collected. All cases were operated on and followed to assess the results of surgery, complications and recurrence.

**Results:** Seven cases were entered in this study (five males and two females). Seventy-one percent of our patients were in the first decade of life. Dyspnea and cough were present in 6(85%) and 5 cases (71%), respectively. Physical exam showed polycythemia in 5 (71%), clubbing in 4(57%) and arterial bruit over the chest in 2 (28%) cases. Two paradoxical emboli were seen, (one to the brain and one to the coronary artery). Family history was negative. Chest x-rays revealed large PAVMs in 5 cases (71%). Diagnosis was made by CT-scan, catheterization, angiography, and histopathology. Location of lesions was in the lower lobes in all cases. Surgical approach was lobectomy in 5 cases and segmentectomy in two cases. Operations were without any complication and the patients were symptom-free thereafter.

**Conclusion:** Surgical resection of large PAVMs was completely curative without any early or late complications. (*Tanaffos* 2006; 5(4): 37-42)

**Key words:** Pulmonary arteriovenous malformation, Pulmonary vascular anomaly, Pulmonary arteriovenous fistula, Surgical treatment

### INTRODUCTION

Direct communications between the branches of pulmonary artery and pulmonary veins, without

an intervening pulmonary bed, called pulmonary arteriovenous malformations (PAVMs), are probably the most common anomalies of the pulmonary vascular tree (1). Table 1 shows a recent classification of PAVMs. This is a relatively rare anomaly and 20% are type II PAVM (2). This type of

Correspondence to: Mirsadraee M

Address: NO 1-30, 2<sup>nd</sup> Aref Street, Ahmadabad Ave. Mashhad-Iran.

Email address: majidmirsadraee@yahoo.com

Received: 7 April 2006

Accepted: 24 December 2006

PAVM is characterized by less than 5 AVMs in the body and no other vascular anomalies i.e. AV fistulas or aneurysms. Most of these patients have a large PAVM and a massive right to left shunt is present; thus, cyanosis and polycythemia are the major clinical findings (1). We studied seven cases of type II PAVMs in which surgical resection was the mainstay of treatment. All were free of symptoms and without relapse during the follow-up period after surgery.

**Table 1.** Anatomical classification of pulmonary artery malformations<sup>16</sup>

<b>Group I</b>
Multiple small arteriovenous fistulas without aneurysm
<b>Group II</b>
Large arteriovenous aneurysm
<b>Group III</b>
A. Large arteriovenous aneurysm( central)
B. Large arteriovenous aneurysm with anomalous venous drainage
C. Multiple small arteriovenous fistulas with anomalous venous drainage
<b>Group IV</b>
A. Large arteriovenous aneurysm with systemic artery communication
B. Large arteriovenous aneurysm without fistula
<b>Group V</b>
Anomalous venous drainage with fistula

**MATERIALS AND METHODS**

During a 26-year period, all subjects with a final diagnosis of PAVM were entered in this cross sectional study. Patients presented with respiratory symptoms (mainly cyanosis). Specific symptoms and signs such as clubbing, platypnea, telangiectasia and orthodeoxia were included in the questionnaire. Hereditary hemorrhagic telangiectasia was ruled out in all of them. Diagnostic work-up consisted of chest x-ray, computed tomography (with or without

intravenous contrast material), cardiac and pulmonary catheterisation and angiography. Based on the extent of pulmonary involvement and lesion size, surgical treatment such as lobectomy or segmentectomy were chosen. All resected lesions were evaluated by a histopathologist to confirm the vascular anomaly. During the follow-up period, patients were followed for complications of surgery, changes in hypoxia, physical activity, and respiratory symptoms. Ethical considerations were followed and informed consents were obtained.

Statistical analysis of this study consisted of descriptive analysis such as frequency, mean and standard deviation (SD).

**RESULTS**

Seven patients were included in this study (five males and two females). All subjects except two cases were in the first decade of life (mean ±SD age of patients was 11 ± 10.78 years) (Table 2).

**Table 2.** Clinical manifestation of patients with type II PAVM

Cases	Age	Dyspnea	Cough	Hemoptysis	Cyanosis	Bruit	Clubbing
1	7	Yes	Yes	Yes	Yes	Yes	No
2	4	Yes	No	Yes	Yes	No	No
3	1.5	Yes	Yes	No	Yes	No	Yes
4	9	Yes	Yes	No	Yes	No	Yes
5	33	Yes	Yes	Yes	No*	Yes	Yes
6	17	No	Yes	Yes	No	No	No
7	8	Yes	No	Yes	Yes	No	Yes

\* This case had low PO<sub>2</sub> in arterial blood gas

Most patients had nonspecific respiratory symptoms upon initial presentation. Dyspnea was present in six cases (85%) as the most prevalent

symptom. Cyanosis, cough and hemoptysis were seen in 5 cases (71 %). Family history of telangiectasia was absent. Physical exam showed cyanosis in five cases (71%), clubbing in 4 cases (57%) and arterial bruit over the chest wall in two cases (28 %) (Table 2). Diagnosis was made based on hypoxemia, infiltration apparent on the chest-x-ray and CT-scan, catheterization, angiography, and histopathology (Table 3).

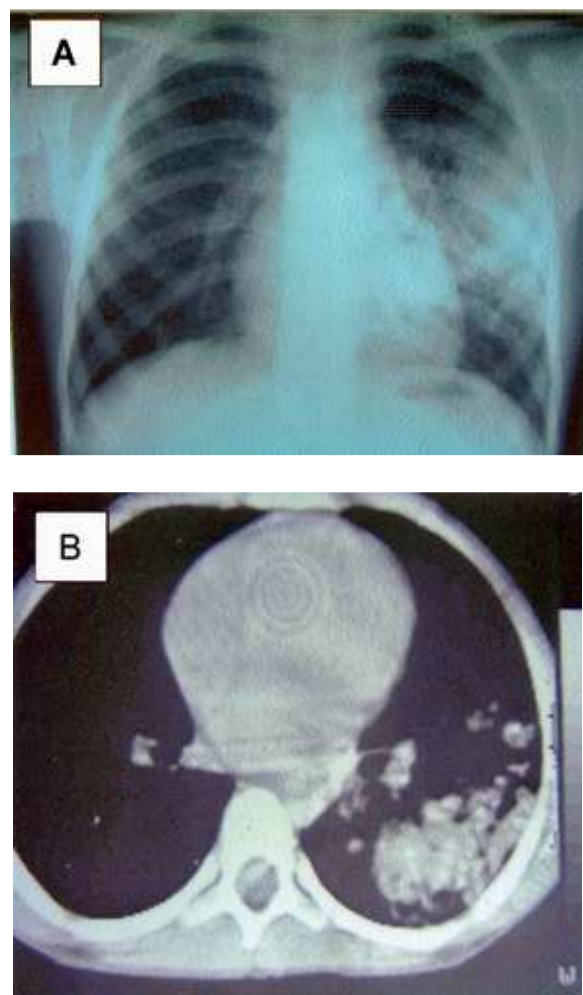
**Table 3.** Diagnostic findings in 7 patients with type II PAVMs.

Cases	Polycythemia	Chest X Ray	Location	Confirmed by
1	Yes	Hilar mass	LLL	CT and Catheterization
2	Yes	Peripheral lesion	LLL	CT and angiography
3	Yes	Normal	LLL	Angiography
4	Yes	Non homogenous opacity	LLL	CT and Catheterization
5	No	Calcified mass	RLL	CT
6	No	Normal	RLL	CT angiography
7	Yes	Large opacity	LLL	CT and angiography

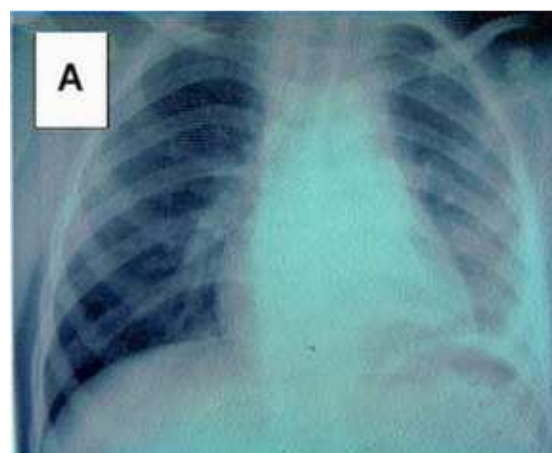
LLL= Left lower lobe, RLL = Right lower lobe, CT = Computed tomography with or without IV enhancement

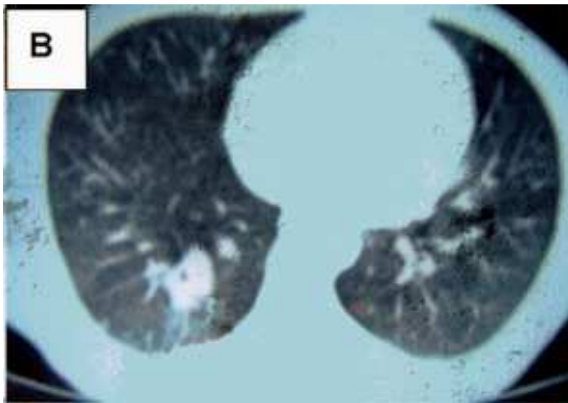
Chest radiography showed a large PAVM in the lower lobes in 5 subjects (71%), but CT-scans showed a round mass compatible with PAVM in all cases (Figure 1 shows the CXR and CT-scan of case 4 and figure 2 shows the CXR and CT-scan of case 5). According to global hypoxemia, all subjects had right to left shunts but catheterization results showed a large shunt (1.8 l/min) in only one subject (case 7). Angiography of this case is shown in figure 3. Paradoxical embolism was seen in two subjects (28%), brain lesion in one (case 1) and paradoxical embolism of the coronary artery in one (case 5). The surgical procedure was lobectomy in 5 subjects (71%) and segmentectomy in 2 subjects (29%). Resection was performed without any complications

and all patients were symptom-free during the follow-up period of 4-26 years.

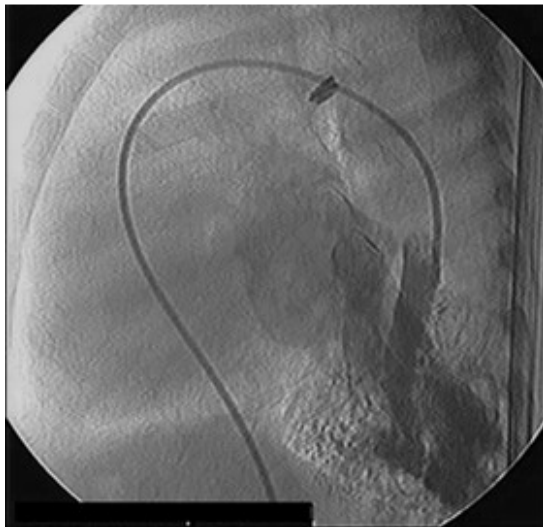

**Figure 1.** (A, B) CXR and CT-scan in a patient with pulmonary arteriovenous malformation (case 4).





**Figure 2.** (A, B) CXR, and CT-scan in a patient with pulmonary arteriovenous malformation (case 5).



**Figure 3.** Pulmonary artery angiography of a patient with a large pulmonary arteriovenous malformation.

## DISCUSSION

PAVMs are uncommon clinical problems. The incidence of PAVM is 2–3 per 100,000 population and the male to female ratio varies from 1:1.5 to 1.8 (1:2.5 in this study). The age at first presentation ranges from newborn to 70 years (3), but in the present study, the majority of our cases were diagnosed in the first three decades of life. Classically, More than 80% of PAVMs are congenital, and out of these, 47%–80% are associated with Osler-Weber-Rendu disease or hereditary haemorrhagic telangiectasia (HHT). Of the

population with HHT, 5% to 15% have a PAVM (3). Secondary or acquired PAVMs although very rare, have been reported in the literature. Causes of secondary PAVMs include chest trauma, thoracic surgery, long-standing hepatic cirrhosis, metastatic carcinoma, mitral stenosis, infections (actinomycosis, schistosomiasis), and systemic amyloidosis (4, 5). All of our cases had congenital anomalies. As like our subjects, most solitary PAVMs are seen in lower lobes, the left lower lobe being the most common location, followed by right lower lobe, left upper lobe (6), right middle lobe, and right upper lobe (1). In this study all lesions were in lower lobes in all subjects.

All PAVMs have an afferent blood supply, usually from one or more branches of the pulmonary artery. However, afferent supply sometimes, in part or all, is derived from the systemic circulation; the source includes the aorta, intercostal and bronchial arteries (7). The efferent limb of an arteriovenous malformation drains into one or more branches of the pulmonary vein; sometimes abnormal efferent vessels may drain directly into the left atrium or inferior vena cava, instead of the pulmonary vein. PAVMs are usually found in close proximity to the visceral pleura or embedded in the outer third of the lung parenchyma. In a study of 110 patients with a single PAVM, 89 (81%) of the lesions were either subpleural or partially embedded in the lung parenchyma (8). Upon microscopic examination the most commonly encountered vascular anomaly is a primitive venous plexus with persistence of large vascular channels of aneurysmal proportions recognized as PAVM.

The classic triad of dyspnea on exertion, cyanosis, and clubbing should alert the clinician to the possibility of a PAVM. A previous report showed this classic triad in 10% of cases (9), but it was detected in 57% of our cases. Bleeding from AVM or endobronchial telangiectasis to the bronchial

lumen may cause hemoptysis, while hemothorax may result from rupture of a subpleural PAVM. Hemoptysis had a high frequency in our cases (71%). In a study of 143 patients with PAVM, who were referred for embolotherapy, 11 (8%) had a history of massive hemoptysis or hemothorax (10).

Physical findings include cyanosis, clubbing and the pulmonary bruit that increased by inspiration and the Muller maneuver (forced inspiration with a closed glottis after full expiration), and this is caused by an increase in the pulmonary blood flow and is decreased by expiration and the Valsalva maneuver, by decreasing venous return to the lung.

The most commonly reported complications relate to the central nervous system (paradoxical embolism). The incidence varies in different series from 28% in our series to up to 59% in Esplin's series (11). Brain paradoxical embolism was confirmed in our first case which was a 7 year-old child. Another case had a history of myocardial infarction at age 32 (case 5). Paradoxical embolism to coronary artery is also possible.

If shunting is minimal, the symptoms are usually subacute or even absent. The peripheral oxygen saturation is low and as expected is not normalized with 100% oxygen (7). If the right-to-left shunt is greater than 20% of the systemic cardiac output or if the desaturated hemoglobin is more than 5 g/dl, the patient will have obvious cyanosis, clubbing, and polycythaemia. Among our cases, two subjects had low shunting and the consequent cyanosis and hemoptysis were the mainstay of diagnosis of PAVM (up to the third decade of life in one subject). Hypoxemia which was not normalized with O<sub>2</sub> therapy aided in the diagnosis of PAVM in this patient.

There is a strong association between PAVM and HHT. All patients with PAVMs should be screened for cerebral arteriovenous malformation by contrast-enhanced brain computed tomography or magnetic

resonance imaging. In a sizeable number of patients (43%–67%), a history of neurological symptoms such as, headache, vertigo, paresis, numbness, paresthesia, syncope, or confusion can be found (6). In one of our subjects brain lesion due to paradoxical embolism and infarction was seen.

Classically, the chest radiograph often suggests the diagnosis of PAVM and the classic radiographic features of PAVM are a round or oval sharply defined mass of uniform density (3- 8), frequently lobulated, and ranging in size from 1–5 cm in diameter; two thirds are located in the lower lobes. But, in our study, chest X ray typical for PAVM was seen in 28% of our cases, and all lesions were located in lower lobes (figures 1 and 2).

Embolotherapy, where available, is a relatively safe and effective procedure and the preferred treatment for PAVMs. The overall success rate was over 99% (808 attempts for 803 PAVM occluded). There was no reported mortality in these series (1). The most commonly encountered complication was self limiting pleuritic chest pain, which was seen in up to 13% of patients and pulmonary infarction in 3%. Air embolism during embolisation is rare, but can cause transient symptoms such as angina, bradycardia, and perioral paresthesias (12). Other reported complications include device migration, myocardial rupture, cerebrovascular accident, vascular injury, early deflation of balloon, deep vein thrombosis, and pulmonary hypertension (13).

Recent evidence showed, surgical resection of PAVMs is indicated in patients who do not respond to embolotherapy, develop serious bleeding complication despite embolotherapy, have intrapleural rupture of the PAVM, or have untreatable contrast allergy or lesions not amenable to embolotherapy (1). In our experience, large PAVM with multiple vascular supply should be added to this list, and this procedure is as safe and well tolerated as more noninvasive procedures.

Temes et al. resected the PAVM via video assisted thoracic surgery (14).

After embolotherapy, the risk of serial growth of occult lesions and recanalisation of the previously embolised PAVMs dictates that patients should have regular follow-up visits.

Like other experts (3-13), follow-up of our cases (from 1.5- 12 years) showed no complications or recurrence of PAVM.

We conclude that surgery is a safe method for treatment of PAVM in selected cases when the PAVM is solitary and large (>2 cm) and the risk of embolotherapy is high (15).

## REFERENCES

1. Khurshid I, Downie GH. Pulmonary arteriovenous malformation. *Postgrad Med J* 2002; 78 (918):191- 7.
2. Sluiter-Eringa H, Orié NG, Sluiter HJ. Pulmonary arteriovenous fistula. Diagnosis and prognosis in noncomplainant patients. *Am Rev Respir Dis* 1969; 100 (2): 177- 88.
3. Dines DE, Arms RA, Bernatz PE, Gomes MR. Pulmonary arteriovenous fistulas. *Mayo Clin Proc* 1974; 49 (7): 460- 5.
4. Symbas PN, Goldman M, Erbesfeld MH, Vlasis SE. Pulmonary arteriovenous fistula, pulmonary artery aneurysm, and other vascular changes of the lung from penetrating trauma. *Ann Surg* 1980; 191 (3): 336- 40.
5. Kamei K, Kusumoto K, Suzuki T. Pulmonary amyloidosis with pulmonary arteriovenous fistula. *Chest* 1989; 96 (6): 1435- 6.
6. Dines DE, Seward JB, Bernatz PE. Pulmonary arteriovenous fistulas. *Mayo Clin Proc* 1983; 58 (3): 176-81.
7. Robertson RJ, Robertson IR. Pulmonary arteriovenous malformations. *Thorax* 1995; 50 (7): 707- 8.
8. Prager RL, Laws KH, Bender HW Jr. Arteriovenous fistula of the lung. *Ann Thorac Surg* 1983; 36 (2): 231- 9.
9. Swanson KL, Prakash UB, Stanson AW, et al. Pulmonary arteriovenous fistulas; Mayo Clinic experience. *Mayo Clinic Proceedings* 1990; 74: 671- 80.
10. Ference BA, Shannon TM, White RI Jr, Zawin M, Burdge CM. Life-threatening pulmonary hemorrhage with pulmonary arteriovenous malformations and hereditary hemorrhagic telangiectasia. *Chest* 1994; 106 (5): 1387- 90.
11. Esplin MS, Varner MW. Progression of pulmonary arteriovenous malformation during pregnancy: case report and review of the literature. *Obstet Gynecol Surv* 1997; 52 (4): 248- 53.
12. Remy-Jardin M, Wattinne L, Remy J. Transcatheter occlusion of pulmonary arterial circulation and collateral supply: failures, incidents, and complications. *Radiology* 1991; 180 (3): 699- 705.
13. Haitjema T, ten Berg JM, Overtom TT, Ernst JM, Westermann CJ. Unusual complications after embolization of a pulmonary arteriovenous malformation. *Chest* 1996; 109 (5): 1401- 4.
14. Temes RT, Paramsothy P, Endara SA, Wernly JA. Resection of a solitary pulmonary arteriovenous malformation by video-assisted thoracic surgery. *J Thorac Cardiovasc Surg* 1998; 116 (5): 878- 9.
15. Georghiou GP, Berman M, Vidne BA, Saute M. Pulmonary arteriovenous malformation treated by lobectomy. *Eur J Cardiothorac Surg* 2003; 24 (2): 328- 30.