

*Tanaffos* (2007) 6(4), 53-57

©2007 NRITLD, National Research Institute of Tuberculosis and Lung Disease, Iran

## Mediastinal Hemangioma: A Case Report

Reza Bagheri <sup>1</sup>, Fariba Rezaeetalab <sup>2</sup>, Mahmood Kalantari <sup>3</sup>, Mohammad-Taghi Rajabi Mashhadi <sup>4</sup>

<sup>1</sup> Department of Thoracic Surgery, <sup>2</sup> Department of Pulmonary Medicine, <sup>3</sup> Department of Pathology, <sup>4</sup> Department of General Surgery, Mashhad University of Medical Sciences, MASHHAD-IRAN.

### ABSTRACT

*Mediastinal hemangioma is a very rare tumor. It may occur at any age but the cavernous form shows a predilection in children and adolescents. Mediastinal hemangioma was diagnosed in a 15-year-old boy from Afghanistan. Cough and neck swelling were his chief complaints. Chest x-ray and CT-scan showed mediastinal widening and anterior mediastinal mass. After cervical biopsy, anterior cervicomediastinal surgery was performed. Pathological examination of the lesion revealed a mediastinal hemangioma. (Tanaffos 2007; 6(4): 53-57)*

**Key words:** Mediastinal hemangioma, Tumor, Children

### INTRODUCTION

Benign vascular tumors are rarely encountered in the mediastinum, but the most common type of these tumors is mediastinal hemangioma (1).

Hemangiomas account for approximately 0.5% of all mediastinal tumors (1-3). The anterior compartment is most often the initial site; but the tumor may also occur in the middle and posterior mediastinum (4).

Mediastinal hemangiomas usually present in the first four decades of life, with a peak incidence in the first decade. Males and females are affected with equal frequency (1, 5). Surgical excision and total resection

is the treatment of choice in such cases (6).

### CASE SUMMARIES

A 15-year-old boy referred from Afghanistan, complaining of chronic cough and neck swelling.

Physical examination revealed a soft mass in the anterior neck that extended to the anterior mediastinum causing a lateral placement of the jugular vein. There was no sign of lymphadenopathy. Physical examination of his chest, abdomen and testes was normal. On laboratory examination, CBC, ESR,  $\beta$ -HCG and  $\alpha$ FP were in the normal limits. Chest x-ray revealed mediastinal widening (Figure 1).

CT-scan showed an anterior mediastinal mass with extension to the neck with a density of 0 to 30 HU along with calcification and phleboliths (Figures 2 and 3).

Correspondence to: Bagheri R

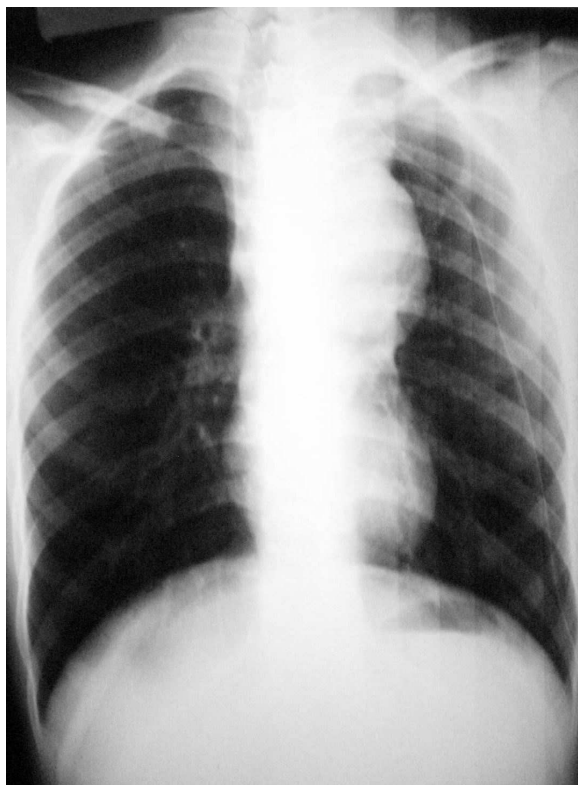
Address: Department of Thoracic Surgery, Mashhad University of Medical Sciences and Health Services, MASHHAD-IRAN

Email address: bagherir@mums.ac.ir

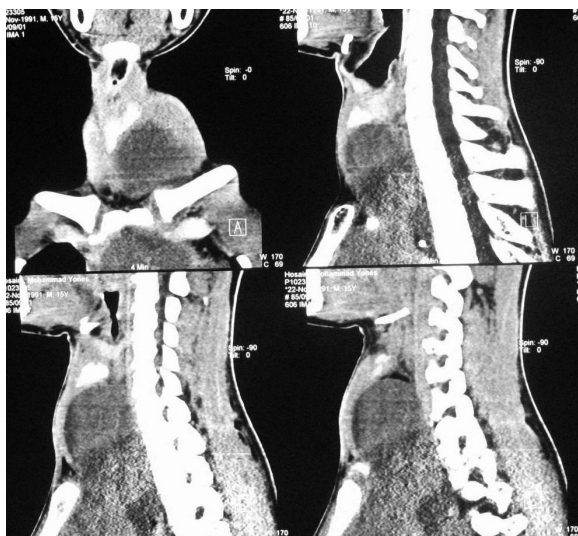
Received: 8 July 2007

Accepted: 17 Nov 2007

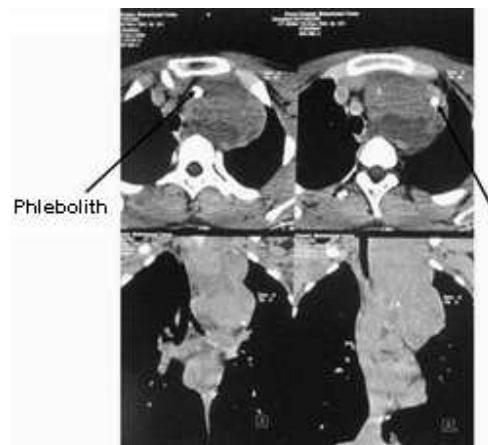
The biopsy sample was taken from the neck mass and the lesion was completely resected by an anterior cervico-mediastinal approach. (7)



**Figure 1.** Chest x-ray of the patient with anterior mediastinal mass with neck extension.

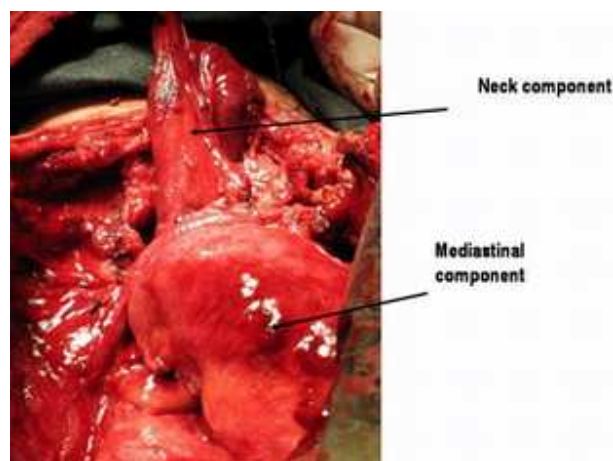


**Figure 2.** CT-scan of the patient with an anterior mediastinal mass extending to neck.

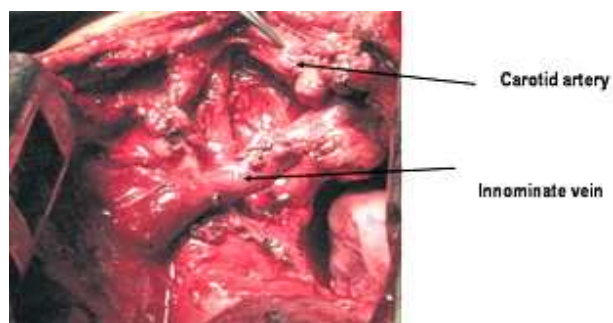


**Figure 3.** CT-scan of the patient with anterior mediastinal mass plus phlebolith (black arrow).

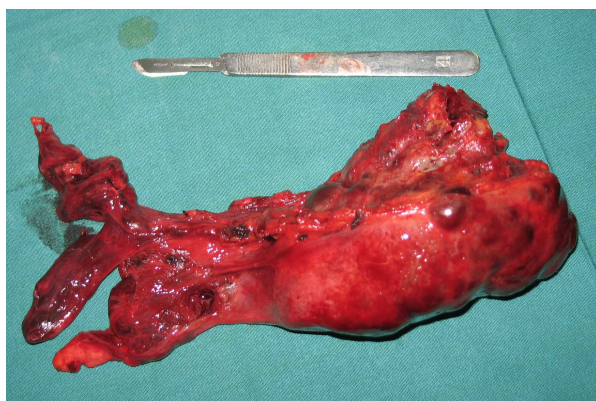
Figures 4 and 5 demonstrate the surgical exploration and Figure 6 shows the macroscopic view of the surgically-resected lesion.



**Figure 4.** Surgical exploration of the tumor via a cervico-mediastinal approach (black arrow shows tumor extension).

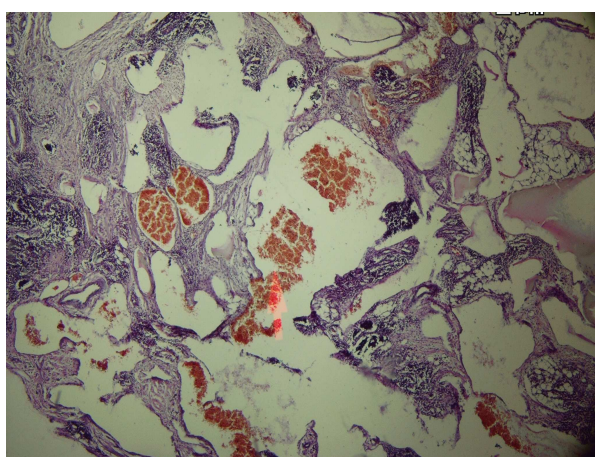


**Figure 5.** Surgical exploration view after complete resection of the tumor.

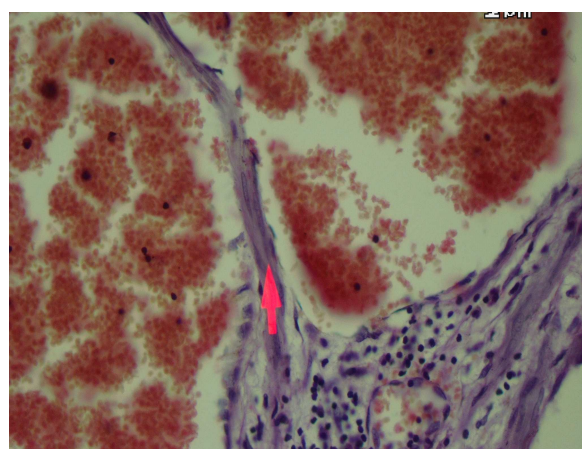


**Figure 6.** Macroscopic view of the surgically resected lesion

Figures 7 and 8 show microscopic views of a mediastinal cavernous hemangioma.

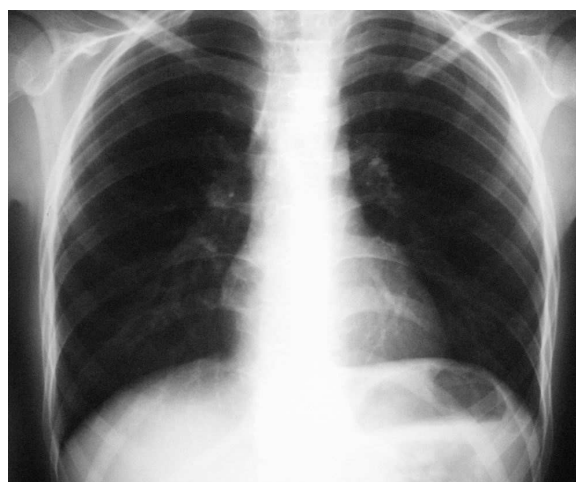


**Figure 7.** Microscopic view of cavernous hemangioma shows dilated vascular spaces filled with RBCs (×25).



**Figure 8.** Section shows dilated vascular spaces lined with flat endothelium (×100).

Figure 9 shows post-operative chest X-ray.



**Figure 9.** Post-operative chest X-ray

## DISCUSSION

Mediastinal tumors comprise a wide spectrum of benign and malignant diseases (8). Vascular tumors of the mediastinum are rare (9). The anterior mediastinum is most often the initial site, but neither the middle nor posterior mediastinum are spared by this lesion (10). Benign tumors are reported in almost 90% of the vascular mediastinal lesions (11). Hemangiomas can be seen in any age group, but the cavernous type is mostly seen in children and adolescents (12). One-third to 1/2 of patients are symptomatic. In the remaining patients the signs and symptoms are the result of infiltration to adjacent structures and include fullness and mass in the neck, chest pain, dyspnea, hemoptysis, superior vena cava syndrome, Horner's syndrome and neurologic complaints (13). Occasionally mediastinal hemangiomas are associated with Osler Weber Randu disease and multiple hemangiomas in other sites of the body (14). The lesion is usually revealed in the chest x-ray (15). Phleboliths may be seen in as many as 10% of these cases (16). Angiography has not been helpful while CT-scan reveals and delineates the lesion and its connection to other structures (17). CT-scan reports an attenuation of 30 Hu, (18) and can possibly suggest the best operative



approach to the mediastinal lesion. MRI is also helpful (19). Gross hemangiomas appear as soft purplish encapsulated masses (20). Microscopically, hemangiomas are divided into three types of capillary, cavernous and venous (21). Cavernous and capillary hemangiomas are the most common types (22) and surgical excision is the treatment of choice. But, some of these tumors which are located in the thoracic apex can produce many problems in decision making due to their extension to neck spaces. Additionally, most of them cannot be totally resected by a thoracotomy approach due to the close attachment of these tumors to large vessels and the removal of these tumors might be followed by severe complications and massive hemorrhage during surgery. (7)

This study presents a case of this kind of tumor operated via an anterior trans-cervico-thoracic approach. In the anterior cervico-mediastinal surgery (7), depending on the tumor development in neck spaces, first a neck space dissection is done with an oblique incision near the sternocleidomastoid muscle. In all patients the clavicular head is resected to see the subclavian vessels; then by continuing the incision, as in a partial sternotomy, the mediastinal space is easily accessed for complete removal of the tumor. For total resection of a mediastinal tumor, the operation can be completed with an anterior thoracotomy whenever required (Figure 10).

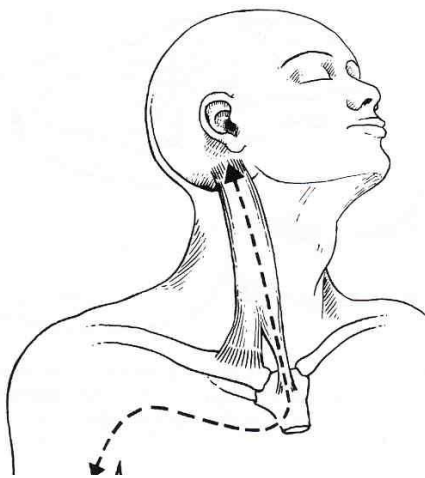


Figure 10. The technique of anterior cervico mediastinal approach

## CONCLUSION

Mediastinal hemangioma is rare. The best method of treatment for this tumor is surgery and the anterior cervico-mediastinal approach may be optimal.

## REFERENCES

1. Cohen AJ, Sbaschnig RJ, Hochholzer L, Lough FC, Albus RA. Mediastinal hemangiomas. *Ann Thorac Surg* 1987; 43 (6): 656- 9.
2. Rodriguez Paniagua JM, Casillas M, Iglesias A. Mediastinal hemangiomas. *Ann Thorac Surg* 1988; 45 (5): 583.
3. Davis JM, Mark GJ, Greene R. Benign blood vascular tumors of the mediastinum. Report of four cases and review of the literature. *Radiology* 1978; 126 (3): 581- 7.
4. BALBAA A, CHESTERMAN JT. Neoplasms of vascular origin in the mediastinum. *Br J Surg* 1957; 44 (188): 545- 55.
5. Cohen AJ , Sbaschnig RJ , Hchholzer L et al : Mediastinal hemangiomas . *Ann Thorac Surg* 1987 : 43 : 656 -9.
6. Kumar P, Judson I, Nicholson AG, Ladas G. Mediastinal hemangioma: successful treatment by alpha-2a interferon and postchemotherapy resection. *J Thorac Cardiovasc Surg* 2002; 124 (2): 404- 6.
7. Bagheri R, Rajabi M, Mashhadinejad H: Anterior thrans cervico thoracic approach for complete resection of cervico thoracic mediastinal tumor. *The Iranian Journal Otorhinolaryngology* 2006; 18: 23-9.
8. Strollo DC, Rosado de Christenson ML, Jett JR. Primary mediastinal tumors. Part 1: tumors of the anterior mediastinum. *Chest* 1997; 112 (2): 511- 22.
9. Cohen AJ, Chamberlain DW, McKneally MF, Weisbrod GL. Anterior mediastinal mass. *Chest* 1993; 103 (5): 1577- 8.
10. Klecker RJ, Sinclair DS, King MA. Case 1. Mediastinal hemangioma. *AJR Am J Roentgenol* 2000; 175 (3): 866; 868-9.
11. Toye R, Armstrong P, Dacie JE. Lymphangiohaemangioma of the mediastinum. *Br J Radiol* 1991; 64 (757): 62- 4.

12. Gindhart TD, Tucker WY, Choy SH. Cavernous hemangioma of the superior mediastinum. Report of a case with electron microscopy and computerized tomography. *Am J Surg Pathol* 1979; 3 (4): 353- 61.
13. Chong KM, Hennox SC, Sheppard MN. Primary hemangiopericytoma presenting as a Pancoast tumor. *Ann Thorac Surg* 1993; 55 (2): 9.
14. Riquet M, Brière J, Le Pimpec-Barthes F, Puyo P. Lymphangiohemangioma of the mediastinum. *Ann Thorac Surg* 1997; 64 (5): 1476- 8.
15. Tarr RW, Page DL, Glick AG, Shaff MI. Benign hemangioendothelioma involving posterior mediastinum: CT findings. *J Comput Assist Tomogr* 1986; 10 (5): 865- 7.
16. Schurawitzki H, Stiglbauer R, Klepetko W, Eckersberger F. CT and MRI in benign mediastinal haemangioma. *Clin Radiol* 1991; 43 (2): 91- 4.
17. Seline TH, Gross BH, Francis IR. CT and MR imaging of mediastinal hemangiomas. *J Comput Assist Tomogr* 1990; 14 (5): 766- 8.
18. Eber CD, Stark P, Kernstine K. Subcarinal cavernous hemangioma: CT findings. *Radiologe* 1995; 35 (5): 354- 5.
19. Ishii K, Maeda K, Hashihira M, Miyamoto Y, Kanegawa K, Kusumoto M, et al. MRI of mediastinal cavernous hemangioma. *Pediatr Radiol* 1990; 20 (7): 556- 7.
20. Moran CA, Suster S. Mediastinal hemangiomas: a study of 18 cases with emphasis on the spectrum of morphological features. *Hum Pathol* 1995; 26 (4): 416- 21.
21. Buckner S, McAllister J, D'Altorio R. Case of the season. Hemangioma of the middle mediastinum. *Semin Roentgenol* 1994; 29 (2): 98- 9.
22. Cohen AJ, et al. Anterior mediastinal mass. *Ann Thorac Surg* 1993; 103: 577.