

Tanaffos (2011) 10(2), 56-68

©2011 NRITLD, National Research Institute of Tuberculosis and Lung Disease, Iran

# Novel Technique for Placement of Laryngeal Mask Airway in Difficult Pediatric Airways

Fatemeh Roodneshin <sup>1</sup>, Mahvash Agah <sup>2</sup>

<sup>1</sup> Department of Anesthesiology and Intensive Care, Labaffinejad Hospital, <sup>2</sup> Anesthesiology Research Center, Shahid Beheshti University of Medical Sciences, Tehran-Iran.

## ABSTRACT

**Background:** The main responsibility of an anesthesiologist is to safely maintain an open airway and preserve sufficient gas exchange in the lungs. This role becomes more significant when managing children especially those with difficult airways (DA). In such cases, a quick appropriate action can decrease the related mortality and morbidity. Laryngeal mask airway (LMA) is a device used in cases with difficult airways. Its placement is much more difficult in children especially those with DA. There is a greater risk of malpositioning and its insertion with routine techniques is sometimes impossible. In this article, we introduce a new method for replacement of LMA in difficult pediatric airways (DPA).

**Materials and Methods:** In this before and after, pre and post design clinical trial, we evaluated 30 children with congenital anomalies and difficult airways who were candidates for elective eye surgery (short term). A written consent was obtained from the parents or the legal guardians of those who met the inclusion criteria. Inhalation anesthesia was induced by sevoflurane. The patients had assisted spontaneous respiration. No muscle relaxant was administered. LMA was inserted using the classic method in the anesthesia depth of BIS=35-40. After 2 unsuccessful attempts according to the criteria for adequate function of LMA, we tried placing the LMA using our innovated method after meeting the primary requirements and reaching the anesthesia depth of 35-40. In this method, the index finger of the left hand was placed on the tongue pushing it downwards (towards the floor of the mouth) when inserting the LMA. This way, we assisted LMA passing down the pharynx resulting in its adequate positioning. Criteria for adequate function of LMA in both classic and innovated insertion methods included monitoring of easy ventilation, no resistance during exhalation, adequate chest movement, no air leakage, optimal airway pressure, optimal lung compliance, level of oxygenation of arterial blood and level of CO<sub>2</sub> at the end of exhalation. In case of presence of air leakage with bag pressure below 15 cm of water, lack of chest movement during inhalation, upper airway pressure over 20 cm of water, SPO<sub>2</sub> lower than 90% and low compliance of the lung, LMA placement would be considered a failure. In such cases, LMA would be immediately extracted and the required depth of anesthesia would be reached using an oxygen mask and required inhalations. Complications occurring during the procedure and after LMA extraction would be recorded.

**Results:** Our understudy population included 30 children in the age range of 1.5 months to 10 yrs (11 girls and 19 boys) who had clear DA criteria due to syndromes and severe congenital anomalies and were candidates for elective eye surgery. Duration of the operation was 30 to 60 minutes. In all 30 cases, LMA placement with the classic method was not successful after 2 attempts by an expert. LMA was successfully inserted for all cases by the same person using the innovated method after meeting the required criteria (BIS=35-40). All ventilation indices were met and the operation was performed successfully with no complication.

**Conclusion:** There is always a risk of unsuccessful LMA placement in difficult pediatric airways using the classic method of insertion. The innovated method recommends pushing down the tongue by the index finger of the left hand. Considering the hypersensitivity of children to hypoxia and risk of unsuccessful LMA placement by the classic method, the innovated placement method is advised in children suffering from anomalies associated with macroglossia. (Tanaffos2011; 10(2): 56-68)

**Key words:** Difficult pediatric airway, LMA, Sevoflurane, Muscle relaxant, Hypoxia

Correspondence to: Agah M

Address: Anesthesiology Research Center, Shahid Beheshti University of Medical Sciences, Tehran, Iran.

Email address: dragahm@yahoo.com

Received: 3 June 2010

Accepted: 5 November 2010

## INTRODUCTION

Having the ability to evaluate the situation and effectively manage and maintain an open airway in a patient is a critical expertise for any anesthesiologist. When encountering an unexpected difficult airway, the anesthesiologist should follow a specific standard program for intubation and reinstating the ventilation of patient (1) because the main responsibility of an anesthesiologist is to safely maintain an open airway and preserve sufficient gas exchange in the lungs by every possible way (2).

Difficult airway (DA) is a major cause of anesthesia related mortality and morbidity and the respiratory adverse events are the main cause of brain death and the resultant morbidity and mortality (3-5). An unanticipated difficult airway is often associated with trauma to the airways and an increased risk for patients especially children (6,7). In such cases, adequate expertise and a professional clinical judgment is definitely required to prevent related morbidity and mortality. Inability to maintain a safe open airway in emergency and critically ill patients can increase the risk and even result in patient's death (8-10). DA is a clinical condition where an expert anesthesiologist faces difficulties in ventilating the airway via a face mask or through tracheal intubation or both (11). Direct laryngoscopy and endotracheal intubation are still a method of choice in maintaining a safe open airway (2). Despite the wide range of devices and methods designed for pediatric intubation, difficult tracheal intubation (DTI) is still a major cause of death due to anesthesia especially in children with congenital airway anomalies and rare syndromes. DTI refers to cases in which intubation cannot be performed after 3 attempts and the anesthesiologists have to choose an alternative strategy (12, 13). However, in some cases management of the airway is extremely difficult even after opting for an alternative method (14). Difficult intubation rate (DIR) has reported to be 1.5- 13%

(15) and the failure rate was reported 4.7% for laryngeal mask (16). DIR in healthy children has not been determined but is high in those with rare diseases and congenital syndromes (17). Unfortunately, the anatomic view has an insignificant value in predicting DA (18). By performing a thorough evaluation of patients before the operation an unanticipated DA can be foreseen (19). When examining the airway, children just like adults cannot cooperate very well. Therefore, it is recommended to use other indices like thyromental distance, position of the chin in relation to the upper lip and etc (20-22).

To date, precise anatomic anomalies that can help predicting a difficult airway have not been defined (23). In anesthesiology, the **Mallampati score**, also **Mallampati classification**, is used to predict the ease of intubation in adults. However, it has a much less value in children due to their lack of cooperation (24). We usually encounter a DA after the induction of general anesthesia in children (11). Awake intubation technique is a gold standard for adults with DA but is not feasible in children because they cannot cooperate. In addition, devices required for managing pediatric DA are usually not available (25). Considering all the above, it seems necessary to find an alternative method for the management of DA in children. We cannot rely on direct laryngoscopy alone because frequent manipulation of the airway can result in upper airway trauma, edema and bleeding (20) and may expose patients to a higher risk for "cannot intubate cannot ventilate" (CICV). In infants and younger children (7, 26) with DA, all the mentioned complications can occur in a larger scale and may result in airway obstruction, severe hypoxemia, pulmonary edema and even death (27). Due to adverse outcomes of hypoxia and hypercapnia, the anesthesiology science tries to describe a specific anatomy to help predict DA cases (28). Most techniques used for cases with DA require

specific equipments. Many of these devices do not come in pediatric sizes and performing related techniques is difficult even in adults and only expert well experienced anesthesiologists can perform them on children (26). In addition, these equipments are expensive and require special care and maintenance like fiberoptic bronchoscope which requires experience and expertise to operate with (29, 30). Surgical approach even in an ideal situation is a time consuming effort and can result in severe hypoxemia. Therefore, it would be wise to save this method as the last resort (31).

Unanticipated difficult airway management (DAM) is a big challenge for the anesthesiologist (32). The aim of facilitating DAM is to decrease the risk of adverse outcome that may include trauma to the airways, cerebral injury, cardiopulmonary arrest and death (4, 7, 27). Laryngeal mask airway is a device inserted into the hypopharynx without direct vision. If placed in its accurate position, it can be used for spontaneous respiration or positive pressure ventilation (PPV)(33). LMA placed by an expert causes much less irritation than the tracheal tube and some compare it to the placement of oropharyngeal airway. LMA can be used in children with upper airway infection. Incidence of bronchospasm with LMA is less than endotracheal tube (ETT) and the respiratory complications decrease by 50% (34).

Using LMA as a routine device for airway management may be associated with some complications. For instance, several attempts might be required for its accurate placement, and there is a risk of aspiration of stomach contents, inflation of the stomach, suboptimal PPV and etc. The incidence of the mentioned complications depends on the performer's expertise (35). Inadequate depth of anesthesia can also result in all of the mentioned complications (36,37). At present, LMA is considered a standard device for pediatric airway management (38, 39). Establishing and maintaining a

patent airway is among the most important critical expertise required in pediatric emergency medicine and in 90% of the cases, LMA is used for airway management (40-42). Pediatric anesthesiologists have greatly improved airway management of children with facial congenital anomalies (like Goldenhar syndrome) which have difficult intubation and ventilation by using LMA (43- 45). LMA is used in pediatric anesthesia for the safe management of difficult pediatric airways (46).

To date, several methods have been presented for the placement of LMA such as classic, reverse classic, inflated cuff methods and etc (47-49). In placement of LMA, the main problem is to pass the posterior wall (50). The incidence of sore throat is 30% with the classic insertion method. This rate is 23.3% when using the inflated cuff method (35). Trauma to the mucosal tissue is also less using the latter method (51). In children, PPV is often feasible via the LMA. However, we should be careful that peak inspiratory pressure does not go over 15cm H<sub>2</sub>O because it would result in stomach inflation, aspiration of the stomach contents and etc (20, 33, 52). Since the larynx is located higher in children compared to adults, correct positioning of LMA is more difficult in children (53). In the reverse classic method, LMA is inserted upside down into the mouth and when resistance is sensed, we give it a 180° twist. Then the cuff is inflated based on the size of LMA (49). According to bronchoscopic and MRI studies the smaller the size of LMA, the higher the incidence of malposition (54). This is because of the fact that pediatric LMAs are similar in structure to those of adults but smaller in size and they are not custom-made for children according to the anatomy of pediatric airways; and therefore, they can easily be malpositioned (53). LMA is really helpful in difficult pediatric airways and intubation (44, 46) because not

only it maintains a secure airway (40, 55) but also provides a conduit for intubation and a rescue airway in CICV cases. LMA is recommended as a part of DA algorithm to facilitate ventilation in adult cases with unsuccessful bag mask ventilation (11). It is used as a routine device for airway ventilation in most patients with Cormack score of 3 and 4 (40). No wonder it is used as a lifesaving and a respiratory emergency device in patients who cannot be intubated especially infants and neonates. In comparison with trans-tracheal jet ventilation, LMA can be inserted more rapidly (56), takes less time to reinstate effective ventilation and has fewer complications (34, 57). Therefore, it should be easily accessible as the first option in CICV cases (56, 58-60). Another advantage of LMA is that there is no need to hold the mandible and anesthesiologist's hands are free, not occupied and do not get tired (57). General anesthesia due to the relative obstruction of the upper airway (that results in relaxation of the pharyngeal muscles), increased viscoelastic resistance, and decreased functional residual capacity (FRC) increases work of breathing (WOB)(61). In comparison with ventilation mask without oral airway and tracheal tube, LMA decreases WOB (62). General anesthesia preferably depresses the genioglossus and other pharyngeal dilator muscles and narrows the pharyngeal airway. Placing an oral airway decreases the WOB down to the level of LMA (63). The first choice for airway management is based on the anesthesiologist's clinical judgment. In cases with DA, the anesthesiologists should pick the easiest method they are expert and experienced in. In case of failure, they can then move on to other techniques that they are less familiar with. However, we have to admit that in cases with difficult intubation, there is a very small chance that an unpracticed method actually works (14).

Infants and children are more at risk for adverse events than adults (26) especially respiratory complications occurring mostly during anesthesia (3, 6, 7, 10, 43, 64). Since O<sub>2</sub> consumption is higher in children the shorter the apnea duration the better and safer for the child (65). Maintaining an open airway is critically important especially in children and in cases with DA and correct positioning of LMA is sometimes not possible using the routine techniques. Therefore, we decided to choose a technique with which we could promptly and successfully reinstate patients' oxygenation and ventilation with no surgical technique. This study aimed to evaluate the efficacy of a new technique for LMA placement in case of failure of the classic method and to compare it with the routine method in children with DA who presented to the Labbafinejad Hospital for elective eye surgery. This study had 2 phases. In phase 1 we used an exploratory method to suggest a new technique and in phase 2 we designed a before and after, pre and post design clinical trial and evaluated the efficacy of the new method for placement of LMA in pediatric DA.

## MATERIALS AND METHODS

In this before and after, pre and post clinical trial 30 children with DA aged below 10 yrs who were candidates for elective eye surgery (less than an hour duration) were evaluated. First, children who had a high risk of difficult intubation (according to Mallampati classification including thyromental distance, mentohyoid distance, mouth opening, temporomandibular joint, macroglossia, malshaped teeth, cleft palate, neck movement range) were selected. Before taking them to the operating room (OR), their parents were fully informed about this new technique and a written informed consent was obtained from them. The child was then transferred

to the OR and anesthesia was induced using inhalation anesthesia method with Mapleson F system. The inhaled concentration of sevoflurane was gradually increased and N<sub>2</sub>O and O<sub>2</sub> were administered as well. The patient's temperature, exhaled CO<sub>2</sub> concentration, arterial blood pressure and anesthesia depth were all thoroughly monitored using a precordial stethoscope and EKG. An IV line was established for the child using angiocat number 22 or 24. In an anesthesia depth of BIS=35-40, ETCO<sub>2</sub>=35 and when spontaneous respiration of the child became shallow without using a muscle relaxant, LMA was inserted by the same expert anesthesiologist (with a history of placing 2000 LMAs) for all patients using the classic method. The quality of child's ventilation was evaluated according to the following criteria: being able to easily ventilate the lungs which is defined by 1) chest movement with no significant resistance or air leakage and 2) no resistance when exhaling which is detected by rapid re-inflation of the reservoir bag. Chest movement is categorized into 3 categories of no movement, fair movement and adequate movement. Air leakage was also divided into 3 groups of zero, small, high. Lung compliance was grouped into 3 levels of low, good and excellent. Capnography, airway pressure and pulse oximeter were also used to evaluate the adequate function of LMA. In case of placement failure which was characterized by lack of adequate ventilation (twisting of LMA, no chest movement, decreased oxygenation, air leakage, etc.), the LMA would be extracted and in the anesthesia depth of 35-40, the same anesthesiologist would make another attempt to place the LMA. In case of no success after 2 attempts, LMA would be removed, inhalation would be continued and in the same depth of anesthesia the new technique would be employed. In this method, mouth is opened, LMA is hold by the

right hand and is inserted into the mouth when its cuff is slightly inflated. Using the index finger of the left hand, the tongue is pushed down towards the floor of the mouth and then the LMA is guided over the tongue posteroinferiorly towards the pharynx. This way we prevent trauma to the mucosa and facilitate maneuvering the tip of LMA into the pharynx avoiding its malpositioning. After insertion of LMA and evaluation of its correct placement according to the related guidelines, the cuff is inflated with air to the extent that there is no air leak. It should be mentioned that anesthesia depth was similar in every attempt for LMA placement and it was maintained at level of 35-40 using N<sub>2</sub>O and sevoflurane. Since the children were DA cases, assisted spontaneous respiration was maintained using sevoflurane and no muscle relaxant.

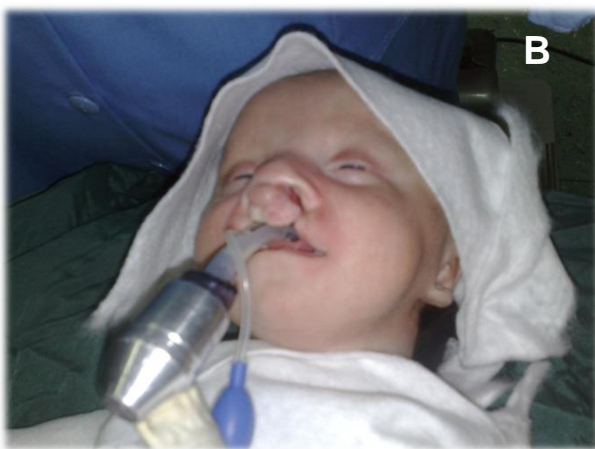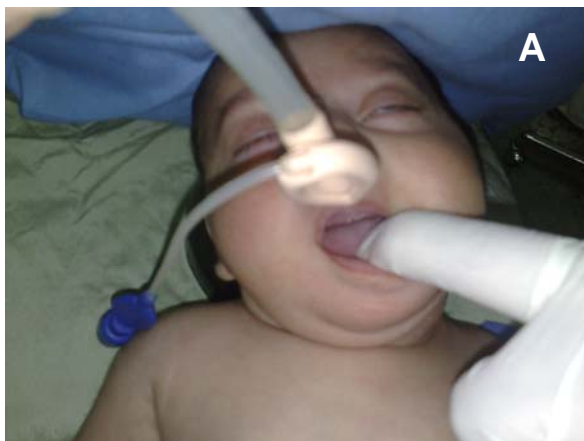
## RESULTS

A total of 30 children with DA (11 girls and 19 boys) in the age range of 1.5 months to 10 years weighing 1.5 to 16 kg who were candidates for ocular surgery entered the study. Duration of surgical operation was 30 to 60 minutes. Causes of DA in these children included Goldenhar syndrome, neurofibromatosis, cleft lip and palate, severe congenital anomalies and etc. Two times attempt for LMA placement using the classic method was not successful in any of the children. No chest movement was observed when pumping the bag, there was a lot of air leakage during inhalation, airway pressure was higher than 20cm H<sub>2</sub>O and lung compliance was low. In all patients, LMA was successfully placed on the first attempt by the same expert anesthesiologist (100%) using the innovated method. When evaluating LMA's adequate position, the chest movement was sufficient in all cases, air leakage was zero after inflating the LMA cuff, lung compliance

was excellent, airway pressure was below 12cm H<sub>2</sub>O and oxygen saturation rate was 100%. All surgical operations were performed successfully (Table 1) and no complication was observed during the operation or when extracting the LMA (Figure 1 A, B).

**Table 1.** Indices for adequate function of LMA in classic and innovated placement methods.

Criteria for adequate LMA function	Classic method	Innovated method
Chest movement	No movement	Adequate movement
Air leakage	High	Zero
Airway pressure cmH <sub>2</sub> O	Over 20cm H <sub>2</sub> O	Below 12cm H <sub>2</sub> O
Lung compliance	Low	Excellent
Arterial blood oxygenation	Less than 90%	100%



**Figure 1.** Placement of LMA using new method.

## DISCUSSION

Our understudy patients were ocular surgery candidates who were suffering from different congenital anomalies and had difficult airway because of anatomical abnormalities of the head and neck, anomalies of the jaws and teeth, macroglossia and abnormal size of the mouth (17, 18, 21, 23, 40, 66, 67). Presence of DA was among the inclusion criteria for our under study subjects. The classic and the new method of LMA placement were studied in these children. Two attempts for LMA placement with the classic method were not successful in any of children. But the new method was successful in the first attempt in all cases and the operation was a success as well. Inability to maintain a safe open airway in critically ill or emergency patients or patients under general anesthesia increases the complications and may even result in death. This is a critical issue in cases with DA (8). Loss of airway in children is a common cause of cardiac arrest (64) and the incidence of pediatric preoperative cardiac arrest (POCA) has reported to be 1.4/10,000. By substituting the halothane with sevoflurane this figure decreases from 37% to 18%. Newborns younger than 30 days old have had the highest rate of cardiac arrest and rate of respiratory problems as the cause has increased from 20% to 27%. In this age group, the most common etiology is laryngospasm (43). Therefore, finding a technique to help maintain a safe open airway in such cases is among the main responsibilities of an anesthesiologist. In this study, we introduced a new method for LMA placement to achieve this goal.

At present, use of LMA as a replacement for intubation has become very popular (20, 38, 57, 58, 68). Since most anesthesiologists are familiar with routine use of LMA and have the required expertise, it is considered a preferred device for the management of unanticipated difficult airway (UDA) (40, 42, 46, 55, 60, 67). In the practice guidelines for

management of difficult airway offered by the "American Society of Anesthesiologists", use of LMA has been recommended in several phases (11). In DA patients, it is important to maintain spontaneous respiration with an inhalation anesthesia drug without using a muscle relaxant (43). In infants and neonates, inhalation anesthesia with sevoflurane while maintaining spontaneous respiration has been introduced as the preferred method (46, 69). This way, we can safely manage the pediatric airway (43). Sevoflurane has been introduced as an excellent choice for a smooth and rapid anesthesia induction (70). Our study results indicated that in DA cases LMA can be placed using the new technique for establishing a safe open airway and maintaining adequate oxygenation. One of the advantages of LMA over tracheal intubation is that LMA does not have the potential extubation difficulties especially in DA cases. This is particularly important in ocular surgery since the patient should have a smooth emergence from general anesthesia with no coughing or agitation (71). In this way, adequate ventilation of the lungs is achieved in a short period of time with minimal trauma to the airways. It should be reminded that LMA placement with whether the classic or the new method requires adequate depth of anesthesia. In order to reach this goal and avoiding the over dose or light anesthesia, anesthesia depth monitor (Bispectral index) could be of great help in regulating the dosage of sevoflurane (72).

In a study by Benumof in 1991, incidence of CICV was estimated to be 0.01-2/10,000 (73) and LMA was shown to be very effective in establishing the ventilation in such cases (40, 74).

Benumof in 1996 successfully used LMA for ventilation and tracheal intubation of cases with DA (56).

Martin et al. in 1999 evaluated the efficacy of LMA for difficult airway management in patients who required ventilation. In these patients, tracheal

intubation was not successful. LMA was placed. They concluded that in cases for whom routine techniques do not work, LMA can be safely and successfully used to quickly and effectively manage the airway (75). We used LMA for DA patients in our study and when the standard method of placement failed, the new technique was employed which was successful in 100% of the cases.

Ellis and colleagues presented a 20-day-old infant with several congenital abnormalities who was a candidate for surgery and was intubated with LMA after the administration of cisatracurium using fiberoptic bronchoscope (76). In our study, no extra device or muscle relaxant was required and LMA was placed with no need for intubation.

Stosks et al. in 2002 reported 2 patients with severe retrognathia and anteriorly positioned larynx in whom intubation was not successful after several attempts. An airway was established in them using LMA. LMA is considered an effective alternative when patient's life is at risk (44). Since our patients had congenital anomalies, we could not place LMA using the classic method but with the new method LMA was successfully placed and helped maintaining an open airway.

Jenkins et al. in their study in 2002 in Canada showed that anesthesiologists are really interested in using intubating LMA (ILMA) in DA cases. According to them, the reasons were first, LMA is not an expensive device and second, it is easily accessible and available in most hospitals in Canada (59).

Bahk et al. in 2002 compared LMA placement using intravenous ketamine and lidocaine spray with intravenous propofol and concluded that propofol causes apnea, hypotension, and pain during injection (77). In our study, we reached the required depth of anesthesia by using sevoflurane. LMA placement was not successful when using the classic method but

by using the new method, it was inserted successfully.

Infosino reported that LMA as an efficient device in control and management of difficult pediatric airways (DPA) (20).

Henderson et al. in 2004 used classic LMA where intubating LMA (ILMA) was not available for secondary tracheal intubation. Success rate in blind intubation via LMA was 93% with no pressure on the cricoid cartilage. This rate has reported to be up to 100% in some studies (4).

In 2005, Grein and Weiner compared LMA, bag mask ventilation and endotracheal intubation in neonatal resuscitation and concluded that in neonates who require PPV for resuscitation, LMA can provide efficient ventilation and a successful resuscitation quicker than the other 2 methods (78).

Manivel et al. in 2005 successfully used LMA for airway management of a 2-year-old child with Klippel-Feil syndrome (79). In our study, we placed LMA using the new method and safely and successfully managed the airway in all our DA cases (inhalation with sevoflurane and maintaining spontaneous respiration).

Connelly et al. (1) evaluated UDA management in teaching hospitals for a 7-year period. According to their findings, whenever direct laryngoscopy was unsuccessful and tracheal intubation could not be performed one of the following methods would be employed:

- 1- Using direct laryngoscopy with extra blades and different sizes (22% success rate)
- 2- Using LMA (88% success rate); by using ILMA this rate reaches 96.5%
- 3- Using Bullard laryngoscope (84% success rate)
- 4- Fiberoptic bronchoscopy (90% success rate)

In our study, success rate for placing the LMA using the new method was 100%.

Timmermann et al. successfully used ILMA for

managing a difficult airway out-of-hospital and performed ILMA intubation and established ventilation in all patients with DA (80). We achieved a 100% success rate in our study using the new method of LMA placement.

In a case series study by Stallmer et al. in 2008 on patients with Klippel-Feil syndrome, LMA was used for ventilation and management of airway. Since intubation with fiberoptic bronchoscope requires several attempts, they recommended managing the airway in such patients by using alternative techniques with higher success rates causing fewer complications. Out of 10 patients in their study, LMA was used in 4 cases (81). In our study, since all our patients were DA cases, we used LMA in the first place and we prevented trauma to the airways.

Kuduvalli et al. in 2008 studied UDA management in anesthetized patients. They showed that using standard LMA and ILMA in CICV cases improves the training and outcomes (82).

In 2008, Chen and Hsiao compared LMA with tracheal tube and demonstrated that LMA is more rapidly inserted, establishes ventilation in a shorter period of time and has fewer complications (83).

In 2009, Macnair et al. in their study compared video laryngoscope with direct laryngoscopy and concluded that video laryngoscope provides a better view but requires more time (84). We did not require direct laryngoscopy in any of our cases.

Taguchi et al. in 2009 presented a case of an 8-year-old boy with Hunter syndrome (Mucopolysaccharidosis type II) and DA. He was anesthetized with sevoflurane and intubated using airway scope and LCD monitor to view the tracheal tube passing the vocal cords. However they admitted that this was a dangerous technique (85). We did not put our patients in any kind of danger by using the new method of LMA placement.

Walker and Ellwood in 2009 studied 34 children



with craniofacial abnormalities and Mucopolysaccharidosis. They placed LMA for them using sevoflurane with spontaneous respiration. They did not encounter a poor airway in any of the cases and reported LMA as an alternative for tracheal tube for maintaining an open safe airway. LMA was really helpful in cases with failed intubation for preserving the oxygenation or working as a conduit for the passing of fiberoptic bronchoscope (46). We also had a 100% success rate for LMA placement using the new method with sevoflurane and maintaining the spontaneous respiration.

Wrightson et al. in their study, successfully used LMA for DA children and infants who were candidates for tracheostomy for airway management and introduced it as a life saving device in unintubated cases (45).

## CONCLUSION

LMA placement is helpful for the management of unanticipated difficult airway in children. The new technique for LMA placement using the index finger of the left hand for pushing down the tongue provides the best position for insertion of LMA. In this study on DA patients, LMA was placed successfully in all cases using our innovated technique; whereas, attempts for LMA placement with the classic method was not successful in them.

## REFERENCES

1. Connelly NR, Ghandour K, Robbins L, Dunn S, Gibson C. Management of unexpected difficult airway at a teaching institution over a 7-year period. *J Clin Anesth* 2006; 18 (3): 198- 204.
2. Oates JD, Macleod AD, Oates PD, Pearsall FJ, Howie JC, Murray GD. Comparison of two methods for predicting difficult intubation. *Br J Anaesth* 1991; 66 (3): 305- 9.
3. Peterson GN, Domino KB, Caplan RA, Posner KL, Lee LA, Cheney FW. Management of the difficult airway: a closed claims analysis. *Anesthesiology* 2005; 103 (1): 33- 9.
4. Henderson JJ, Popat MT, Latto IP, Pearce AC. Difficult Airway Society. Difficult Airway Society guidelines for management of the unanticipated difficult intubation. *Anaesthesia* 2004; 59 (7): 675- 94.
5. Xue FS, Zhang GH, Li P, Sun HT, Li CW, Liu KP, et al. The clinical observation of difficult laryngoscopy and difficult intubation in infants with cleft lip and palate. *Paediatr Anaesth* 2006; 16 (3): 283- 9.
6. Mamie C, Habre W, Delhumeau C, Argiroffo CB, Morabia A. Incidence and risk factors of perioperative respiratory adverse events in children undergoing elective surgery. *Paediatr Anaesth* 2004; 14 (3): 218- 24.
7. Xue FS, Liao X, Li CW, Xu YC, Yang QY, Liu Y, et al. Clinical experience of airway management and tracheal intubation under general anesthesia in patients with scar contracture of the neck. *Chin Med J (Engl)* 2008; 121 (11): 989- 97.
8. Rosenblatt WH, Murphy M. The intubating laryngeal mask: use of a new ventilating-intubating device in the emergency department. *Ann Emerg Med* 1999; 33 (2): 234- 8.
9. White M, Weale N, Nolan J, Sale S, Bayley G. Comparison of the Cobalt Glidescope video laryngoscope with conventional laryngoscopy in simulated normal and difficult infant airways. *Paediatr Anaesth* 2009; 19 (11): 1108- 12.
10. Bunchungmongkol N, Somboonviboon W, Suraseranivongse S, Vasinanukorn M, Chau-in W, Hintong T. Pediatric anesthesia adverse events: the Thai Anesthesia Incidents Study (THAI Study) database of 25,098 cases. *J Med Assoc Thai* 2007; 90 (10): 2072- 9.
11. American Society of Anesthesiologists Task Force on Management of the Difficult Airway. Practice guidelines for management of the difficult airway: an updated report by the American Society of Anesthesiologists Task Force on Management of the Difficult Airway. *Anesthesiology* 2003; 98 (5): 1269- 77. Erratum in: *Anesthesiology* 2004; 101 (2): 565.
12. Moschini V, Collini R. Preauricular skin tags and difficult tracheal intubation: a case report. *Minerva Anestesiol* 2009; 75 (10): 591- 4.

13. Matsumoto T, de Carvalho WB. Tracheal intubation. *J Pediatr (Rio J)* 2007; 83 (2 Suppl): S83- 90.
14. Heidegger T, Gerig HJ, Ulrich B, Kreienbühl G. Validation of a simple algorithm for tracheal intubation: daily practice is the key to success in emergencies--an analysis of 13,248 intubations. *Anesth Analg* 2001; 92 (2): 517-22.
15. Mallampati SR, Gatt SP, Gugino LD, Desai SP, Waraksa B, Freiberger D, et al. A clinical sign to predict difficult tracheal intubation: a prospective study. *Can Anaesth Soc J* 1985; 32 (4): 429- 34.
16. Rose DK, Cohen MM. The airway: problems and predictions in 18,500 patients. *Can J Anaesth* 1994; 41 (5 Pt 1): 372- 83.
17. Frei FJ, Ummenhofer w. Difficult intubation in pediatrics. *Pediatric Anesthesia* 1996; 6(4): 251-63.
18. Bevilacqua S, Gelsomino S, Romagnoli S. Difficult intubation in pediatric cardiac surgery. *Journal of Cardiothoracic and vascular Anesthesia* 2006; 20(2): 291.
19. Hawthorne L, Wilson R, Lyons G, Dresner M. Failed intubation revisited: 17-yr experience in a teaching maternity unit. *Br J Anaesth* 1996; 76 (5): 680- 4.
20. Infosino A. Pediatric upper airway and congenital anomalies. *Anesthesiol Clin North America* 2002; 20 (4): 747-66.
21. Mathew M, Hanna LS, Aldrete JA. Preoperative indices to anticipate difficult tracheal intubation. *Anesth Analg* 1989; 68: S187.
22. Krobbuaban B, Diregpoke S, Kumkeaw S, Tanomsat M. The predictive value of the height ratio and thyromental distance: four predictive tests for difficult laryngoscopy. *Anesth Analg* 2005; 101 (5): 1542- 5.
23. Bellhouse CP, Doré C. Criteria for estimating likelihood of difficulty of endotracheal intubation with the Macintosh laryngoscope. *Anaesth Intensive Care* 1988; 16 (3): 329- 37.
24. Kopp VJ, Bailey A, Calhoun PE, et al. Utility of the mallampati classification for predicting difficult intubation in pediatric patients. *Anesthesiology* 1995; 83: 1147.
25. Carr RJ, Beebe DS, Belani KG. The difficult pediatric Airway. *Seminars in Anesthesia, Perioperative Medicine and Pain* 2001; 20 (3): 219- 27.
26. Borland LM, Colligan J, Brandom BW. Frequency of anesthesia-related complications in children with Down syndrome under general anesthesia for noncardiac procedures. *Paediatr Anaesth* 2004; 14 (9): 733- 8.
27. Wilder RT, Belani KG. Fiberoptic intubation complicated by pulmonary edema in a 12-year-old child with Hurler syndrome. *Anesthesiology* 1990; 72 (1): 205- 7.
28. Karkouti K, Rose DK, Wigglesworth D, Cohen MM. Predicting difficult intubation: a multivariable analysis. *Can J Anaesth* 2000; 47 (8): 730- 9.
29. Stackhouse RA. Fiberoptic airway management. *Anesthesiol Clin North America* 2002; 20 (4): 933- 51.
30. Kristensen MS, Møller J. Airway management behaviour, experience and knowledge among Danish anaesthesiologists--room for improvement. *Acta Anaesthesiol Scand* 2001; 45 (9): 1181- 5.
31. Melillo EP, Hawkins DJ, Lynch L, Macnamara A. Difficult airway management of a child impaled through the neck. *Paediatr Anaesth* 2001; 11 (5): 615- 7.
32. Rosenstock C, Hansen EG, Kristensen MS, Rasmussen LS, Skak C, Østergaard D. Qualitative analysis of unanticipated difficult airway management. *Acta Anaesthesiol Scand* 2006; 50 (3): 290- 7.
33. Badr A, Tobias JD, Rasmussen GE, Stokes DC, Neblett WW 3rd, Campbell P. Bronchoscopic airway evaluation facilitated by the laryngeal mask airway in pediatric patients. *Pediatr Pulmonol* 1996; 21 (1): 57- 61. Erratum in: *Pediatr Pulmonol* 1996; 22 (2): 140.
34. Tait AR, Pandit UA, Voepel-Lewis T, Munro HM, Malviya S. Use of the laryngeal mask airway in children with upper respiratory tract infections: a comparison with endotracheal intubation. *Anesth Analg* 1998; 86 (4): 706- 11.
35. Brimacombe J, Berry A. Insertion of the laryngeal mask airway--a prospective study of four techniques. *Anaesth Intensive Care* 1993; 21 (1): 89- 92.
36. Asai T, Vaughan RS. Misuse of the laryngeal mask airway. *Anaesthesia* 1994; 49 (6): 467- 9.

37. Aantaa R, Takala R, Muittari P. Sevoflurane EC50 and EC95 values for laryngeal mask insertion and tracheal intubation in children. *Br J Anaesth* 2001; 86 (2): 213- 6.
38. Lopez- Gil M, Brimacombe J, Alvarez M. Safety and efficacy of the laryngeal mask airway: A prospective survey of 1400 children. *Anaesthesia* 1996; 51(10): 969-72.
39. Ho AM, Karmakar MK, Dion PW. Choosing the correct laryngeal mask airway sizes and cuff inflation volumes in pediatric patients. *J Emerg Med* 2008; 35 (3): 299- 300.
40. Kinouchi K. Management of difficult pediatric airway. *Masui* 2006; 55 (1): 24- 32.
41. Stringer KR, Bajenov S, Yentis SM. Training in airway management. *Anaesthesia* 2002; 57 (10): 967- 83. Erratum in: *Anaesthesia* 2003; 58 (1): 105.
42. Losek JD, Olson LR, Dobson JV, Glaeser PW. Tracheal intubation practice and maintaining skill competency: survey of pediatric emergency department medical directors. *Pediatr Emerg Care* 2008; 24 (5): 294- 9.
43. Linda J Mason. Problems and pitfalls in pediatric Anesthesia. International Anesthesia Research Society 2008; 106(4):1-5.
44. Stocks RM, Egerman R, Thompson JW, Peery M. Airway management of the severely retrognathic child: use of the laryngeal mask airway. *Ear Nose Throat J* 2002; 81 (4): 223- 6.
45. Wrightson F, Soma M, Smith JH. Anesthetic experience of 100 pediatric tracheostomies. *Paediatr Anaesth* 2009; 19 (7): 659- 66.
46. Walker RW, Ellwood J. The management of difficult intubation in children. *Paediatr Anaesth* 2009; 19 Suppl 1: 77- 87.
47. Brain AI. The laryngeal mask--a new concept in airway management. *Br J Anaesth* 1983; 55 (8): 801- 5.
48. Haynes SR, Morton NS. The laryngeal mask airway: A review of its use in Pediatric Anesthesia. *Pediatr Anaesth* 1993; 3:65-73.
49. Soh CR, Ng AS. Laryngeal mask airway insertion in paediatric anaesthesia: comparison between the reverse and standard techniques. *Anaesth Intensive Care* 2001; 29 (5): 515- 9.
50. Brain AIJ, Denman WT, Goudsouzian NG. Laryngeal mask airway instructional manual. San Diego, CA, Gensia, Inc, 1995.
51. Young TM. The Laryngeal Mask in dental anaesthesia. *Eur J Anaesthesiol Suppl* 1991; 4: 53- 9.
52. Inagawa G, Okuda K, Miwa T, Hiroki K. Higher airway seal does not imply adequate positioning of laryngeal mask airways in paediatric patients. *Paediatr Anaesth* 2002; 12 (4): 322- 6.
53. Park C, Bahk JH, Ahn WS, Do SH, Lee KH. The laryngeal mask airway in infants and children. *Can J Anaesth* 2001; 48 (4): 413- 7.
54. Rowbottom SJ, Simpson DL, Grubb D. The laryngeal mask airway in children. A fiberoptic assessment of positioning. *Anaesthesia* 1991; 46 (6): 489- 91.
55. Asai T, Nagata A, Shingu K. Awake tracheal intubation through the laryngeal mask in neonates with upper airway obstruction. *Paediatr Anaesth* 2008; 18 (1): 77- 80.
56. Benumof JL. Laryngeal mask airway and the ASA difficult airway algorithm. *Anesthesiology* 1996; 84 (3): 686- 99.
57. White P, Smith I. Laryngeal mask airway, Airway Management Principles and Practice. Edited by Benumof JL. St. Louis. Mosby. 1995, PP 353-73.
58. Gruppo di Studio SIAARTI "Vie Aeree Difficili", Frova G, Guarino A, Petrini F, Merli G, Sorbello M, et al. Recommendations for airway control and difficult airway management in paediatric patients. *Minerva Anesthesiol* 2006; 72 (9): 723- 48.
59. Jenkins K, Wong DT, Correa R. Management choices for the difficult airway by anesthesiologists in Canada. *Can J Anaesth* 2002; 49 (8): 850- 6. Erratum in: *Can J Anaesth* 2003; 50 (6): 625.
60. Ezri T, Szmuk P, Warters RD, Katz J, Hagberg CA. Difficult airway management practice patterns among anesthesiologists practicing in the United States: have we made any progress? *J Clin Anesth* 2003; 15 (6): 418- 22.
61. Keidan I, Fine GF, Kagawa T, Schneck FX, Motoyama EK. Work of breathing during spontaneous ventilation in

- anesthetized children: a comparative study among the face mask, laryngeal mask airway and endotracheal tube. *Anesth Analg* 2000; 91 (6): 1381- 8.
62. Joshi GP, Morrison SG, White PF, Miciotto CJ, Hsia CC. Work of breathing in anesthetized patients: laryngeal mask airway versus tracheal tube. *J Clin Anesth* 1998; 10 (4): 268-71.
  63. Mathru M, Esch O, Lang J, Herbert ME, Chaljub G, Goodacre B, et al. Magnetic resonance imaging of the upper airway. Effects of propofol anesthesia and nasal continuous positive airway pressure in humans. *Anesthesiology* 1996; 84 (2): 273- 9.
  64. Bhananker SM, Ramamoorthy C, Geiduschek JM, Posner KL, Domino KB, Haberkern CM, et al. Anesthesia-related cardiac arrest in children: update from the Pediatric Perioperative Cardiac Arrest Registry. *Anesth Analg* 2007; 105 (2): 344- 50.
  65. Motoyama EK, Fine GF, Jacobson KH, Fertal KM, Miyao H. Accelerated Increases in End-Tidal CO<sub>2</sub> (PETCO<sub>2</sub>) in Anesthetized Infants and Children during Rebreathing. *American Society of Anesthesiologists* 2001; 94: A-1276.
  66. Uezono S, Holzman RS, Goto T, Nakata Y, Nagata S, Morita S. Prediction of difficult airway in school-aged patients with microtia. *Paediatr Anaesth* 2001; 11 (4): 409- 13.
  67. Sukhupragarn W, Rosenblatt WH. Airway management in a patient with Goldenhar syndrome: a case report. *J Clin Anesth* 2008; 20 (3): 214- 7.
  68. Sinha A, Sharma B, Sood J. ProSeal as an alternative to endotracheal intubation in pediatric laparoscopy. *Paediatr Anaesth* 2007; 17 (4): 327- 32.
  69. Cardwell M, Walker RW. Management of difficult pediatric airway. *Br J Anaesth* 2003; 3(6), 167-70.
  70. Keleş GT, Toprak V, Ok G, Lüleci N. Volatile induction and maintenance of anesthesia using laryngeal mask airway in pediatric patients. *J Anesth* 2004; 18 (1): 51- 4.
  71. Afzal M. Airway management in paediatric anesthesia: Laryngeal mask airway versus endotracheal tube. *The Internet Journal of Anesthesiology* 2007; 13(1).
  72. Monk TG, Saini V, Weldon BC, Sigl JC. Anesthetic management and one-year mortality after noncardiac surgery. *Anesth Analg* 2005; 100(1): 4-10.
  73. Benumof JL. Management of the difficult adult airway. With special emphasis on awake tracheal intubation. *Anesthesiology* 1991; 75 (6): 1087- 110. Erratum in: *Anesthesiology* 1993; 78 (1): 224.
  74. Parmet JL, Colonna-Romano P, Horrow JC, Miller F, Gonzales J, Rosenberg H. The laryngeal mask airway reliably provides rescue ventilation in cases of unanticipated difficult tracheal intubation along with difficult mask ventilation. *Anesth Analg* 1998; 87 (3): 661- 5.
  75. Martin SE, Ochsner MG, Jarman RH, Agudelo WE, Davis FE. Use of the laryngeal mask airway in air transport when intubation fails. *J Trauma* 1999; 47 (2): 352- 7.
  76. Ellis DS, Potluri PK, O'Flaherty JE, Baum VC. Difficult airway management in the neonate: a simple method of intubating through a laryngeal mask airway. *Paediatr Anaesth* 1999; 9 (5): 460- 2.
  77. Bahk JH, Sung J, Jang IJ. A comparison of ketamine and lidocaine spray with propofol for the insertion of laryngeal mask airway in children: a double-blinded randomized trial. *Anesth Analg* 2002; 95 (6): 1586- 9, table of contents.
  78. Grein AJ, Weiner GM. Laryngeal mask airway versus bag-mask ventilation or endotracheal intubation for neonatal resuscitation. *Cochrane Database Syst Rev* 2005; (2): CD003314.
  79. Manivel S, Prasad R, Jacob R. Anesthetic management of a child with Klippel-Feil syndrome in the radiology suite. *Paediatr Anaesth* 2005; 15 (2): 171- 2.
  80. Timmermann A, Russo SG, Rosenblatt WH, Eich C, Barwing J, Roessler M, et al. Intubating laryngeal mask airway for difficult out-of-hospital airway management: a prospective evaluation. *Br J Anaesth* 2007; 99 (2): 286- 91.
  81. Stallmer ML, Vanaharam V, Mashour GA. Congenital cervical spine fusion and airway management: a case series of Klippel-Feil syndrome. *J Clin Anesth* 2008; 20 (6): 447- 51.

82. Kuduvalli PM, Jervis A, Tighe SQ, Robin NM. Unanticipated difficult airway management in anaesthetised patients: a prospective study of the effect of mannequin training on management strategies and skill retention. *Anaesthesia* 2008; 63 (4): 364- 9.
83. Chen L, Hsiao AL. Randomized trial of endotracheal tube versus laryngeal mask airway in simulated prehospital pediatric arrest. *Pediatrics* 2008; 122 (2): e294- 7.
84. Macnair D, Baraclough D, Wilson G, Bloch M, Engelhardt T. Pediatric airway management: comparing the Berci-Kaplan Video Laryngoscope with direct laryngoscopy. *Paediatr Anaesth* 2009; 19 (6): 577- 80.
85. Taguchi S, Kusunoki S, Fukuda H, Hamada H, Kawamoto M. Difficult tracheal intubation using airway scope in a pediatric patient with Hunter syndrome. *Masui* 2009; 58 (10): 1278- 81.