

# Letter to the Editor on “Percutaneous Dilational Tracheostomy without Bronchoscopy :Placement is Safe, Reintervention is Not.”

**Micah T. Long<sup>1</sup>, Melissa Murray<sup>2</sup>**

<sup>1</sup> Department of Anesthesiology, University of Wisconsin School of Medicine and Public Health, Madison, WI, USA

<sup>2</sup> Department of Emergency Medicine, University of Wisconsin School of Medicine and Public Health, Madison, WI, USA

*Corresponding Author: Long MT*

*Address: Department of Anesthesiology, University of Wisconsin School of Medicine and Public Health, Madison, USA*

*Email address: mtlong@wisc.edu*

To the Editors:

We read with great interest the recent report entitled “Performing Percutaneous Dilational Tracheostomy Without Using Fiberoptic Bronchoscope”. This descriptive study reviewed 70 cases of the aforementioned procedure and concluded that it was efficient and safe (1). This is supported by prior work, (2,3) noting however that this technique is frequently preempted by any suspicion of difficult airway anatomy, for prior history of airway problems and for those patients who have had a previous tracheostomy. Thus, some authors have argued that bronchoscopic guidance improves safety (4). Nonetheless, due to the expanding performance of percutaneous dilational tracheostomy without bronchoscopy, some physicians may attempt to manipulate or replace newly placed tracheostomy tubes without bronchoscopy for problems such as cuff rupture. This may pose a severe risk to patients.

## **Summary**

Percutaneous dilational tracheostomy is a safe approach to the surgical airway in critically ill adults and may be performed safely without bronchoscopic guidance. Manipulation of an existing, newly placed tracheostomy, however, mandates measures to increase safety due to the potential for airway edema.

A postoperative patient suffered from a tracheostomy tube cuff rupture requiring tube exchange two days after percutaneous tracheostomy. The airway was remarkably swollen and rescuing a complication via direct or indirect laryngoscopy would likely have been impossible.

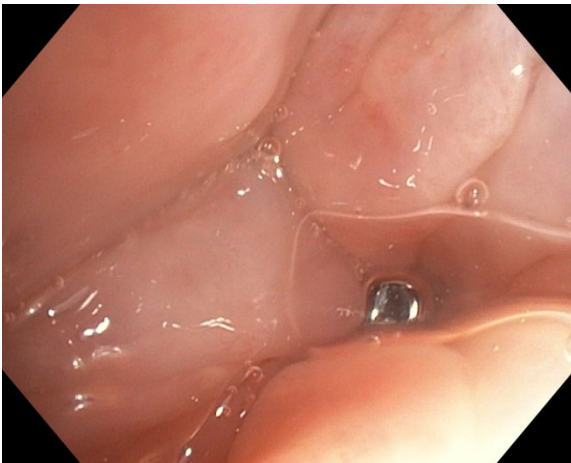To improve safety in case of tracheostomy exchange failure, we loaded an endotracheal tube onto the bronchoscope, entered the subglottic airway and performed the procedure under bronchoscopic visualization. This would enable orotracheal reintubation rescue via the bronchoscope in case of emergency.

While initial percutaneous tracheostomy may be performed safely without bronchoscopy, when intervening on a recently placed tracheostomy it is crucial to enhance safety with bronchoscopy.

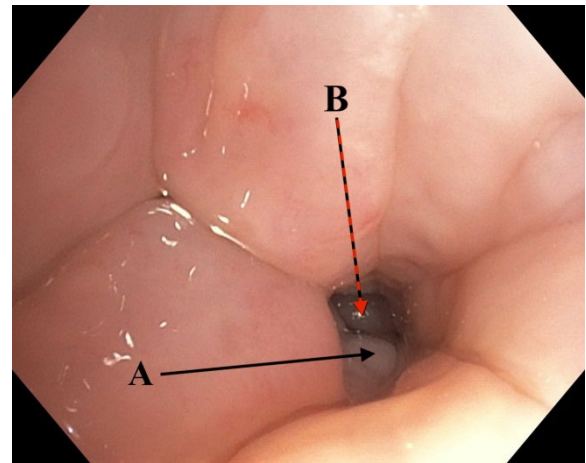
## Case Report

Written consent was obtained from the patient to discuss the following case. We cared for a 69-year-old man with a past medical history of severe chronic obstructive pulmonary disease with chronic exertional dyspnea, coronary artery disease, prior transient ischemic attack, hypertension and active smoking. He presented to the hospital for management of a symptomatic type-IV thoracoabdominal aortic aneurysm. His postoperative course was complicated, including a massive pulmonary embolism and two extubation failures.

An 8.0 cuffed Shiley tracheostomy tube was placed on post-procedure day 18 using a Ciaglia Blue Rhino® G2 advanced percutaneous tracheostomy introducer and tray (Cook Medical, Bloomington, IN) (5). Two days later the tracheostomy was slowly but continually leaking, causing derecruitment and hypoxia. Prior intubations were performed via indirect laryngoscopy showing easy views of normal anatomy, and the patient had no external neck swelling, edema or anatomic abnormalities. Nonetheless, bronchoscopic visualization of the airway was exquisitely challenging (Figures 1 & 2) and severe enough to have precluded direct or indirect laryngoscopy guided orotracheal reintubation of the airway in case of emergency. To improve safety in case of tracheostomy exchange failure, we loaded an endotracheal tube onto the bronchoscope, entered the subglottic airway and performed the procedure under bronchoscopic visualization. This would enable orotracheal reintubation rescue via the bronchoscope. Thankfully, the procedure was uncomplicated. It was discovered that the tracheostomy cuff had a small puncture hole.



**Figure 1.** Initial bronchoscopic view of the glottis above the level of the vocal cords with significant edema and poor visualization of anatomic landmarks .



**Figure 2.** Improved visualization of vocal cords with suctioning and jaw thrust. A) Left arytenoid cartilage, B) inflated tracheostomy balloon.

## Discussion

We conclude that added caution is mandated when manipulating a recently placed tracheostomy as replacement of the tracheostomy could fail, even with the use of a bougie catheter (6), which would require orotracheal intervention “from above.” Even with previously unremarkable intubations and airway anatomy, tracheostomy placement can cause or coincide with glottic edema that could cause failure of direct or indirect laryngoscopy. A catastrophic complication can be avoided by using bronchoscopy with a loaded endotracheal tube.

## REFERENCES

1. Yaghoubi S, Massoudi N, Fathi M, Nooraei N, Khezri MB, Abdollahi S. Performing Percutaneous Dilational Tracheostomy without using Fiberoptic Bronchoscope. *Tanaffos* 2020;19(1):60-65.

2. Abdulla S, Conrad A, Vielhaber S, Eckhardt R, Abdulla W. Should a percutaneous dilational tracheostomy be guided with a bronchoscope? *B-ENT* 2013;9(3):227-34.
3. Dennis BM, Eckert MJ, Gunter OL, Morris JA Jr, May AK. Safety of bedside percutaneous tracheostomy in the critically ill: evaluation of more than 3,000 procedures. *J Am Coll Surg* 2013;216(4):858-65; discussion 865-7.
4. Jackson LS, Davis JW, Kaups KL, Sue LP, Wolfe MM, Bilello JF, et al. Percutaneous tracheostomy: to bronch or not to bronch--that is the question. *J Trauma* 2011;71(6):1553-6.
5. Cook Medical. Ciaglia Blue Rhino® G2 advanced percutaneous tracheostomy introducer set and tray. Cook Medical. [www.cookmedical.com/products/cc\\_ptis\\_webds/](http://www.cookmedical.com/products/cc_ptis_webds/). Published 2019. Accessed May 5, 2019.
6. Casserly P, Lang E, Fenton JE, Walsh M. Assessment of healthcare professionals' knowledge of managing emergency complications in patients with a tracheostomy. *Br J Anaesth* 2007;99(3):380-3.