

Tanaffos (2009) 8(2), 59-63

©2009 NRITLD, National Research Institute of Tuberculosis and Lung Disease, Iran

Primary Pulmonary Hemangiopericytoma: A Case Report

Reza Bagheri¹, Fariba Rezaeitalab², Mahmoud Kalantari³, Mohammad Taghi Rajabi Mashhadi⁴

¹ Department of Thoracic Surgery, ² Department of Pulmonary Diseases, ³ Department of Pathology, ⁴ Department of General Surgery, Mashhad University of Medical Sciences, MASHHAD-IRAN.

ABSTRACT

Hemangiopericytoma is a mesenchymal neoplasm originating from the pericyte, a cell type that surrounds the capillaries. Its primary localization in the lung is extremely rare.

A 70-year-old woman was referred to our hospital complaining of cough and non-massive hemoptysis from 2 months earlier. She was a nonsmoker with a history of close contact with sheep and a dog. On physical examination, she had reduced respiratory sounds in the left upper zone. Her chest x-ray revealed a mass in the left middle and upper zones. CT-scan of the lungs revealed a parenchymal mass with -4 to 20 (HU) densities. Hemagglutination test was negative for hydatid cyst. Fiberoptic bronchoscopy was normal; therefore, the patient underwent surgical operation. The pathology of the mass was primary pulmonary hemangiopericytoma. (Tanaffos 2009; 8(2):59-63)

Key words: Hemangiopericytoma, Pulmonary, Tumor

INTRODUCTION

Hemangiopericytomas are unusual sarcomas originating from capillary pericytic cells and are commonly located in the soft tissue of the thigh and retroperitoneum (1). Hemangiopericytoma of the lung is extremely rare. The age range of patients is wide (4–73 years; mean age: 45 years) and no sex predilection has been noticed. About half the patients are asymptomatic, while the remainder complain of cough, hemoptysis or chest pain (2). We report a case

of primary pulmonary hemangiopericytoma in an elderly woman.

CASE SUMMARY

A 70-year-old woman with chronic cough and non-massive hemoptysis from two months earlier was referred to our hospital. She had no fever, chills or night sweat. There was no change in her appetite or weight and she was a nonsmoker. She had a sheep husbandry. Therefore, she was in close contact with sheep and a dog. There was no history of a similar disease in her family. On physical examination, her vital signs were normal and chest auscultation revealed reduced sounds in the upper zone of the left lung. Lymphadenopathy, splenomegaly and

Correspondence to: Bagheri R

Address: Department of Thoracic Surgery, Mashhad University of Medical Sciences, MASHHAD, IRAN.

Email address: bagherir@mums.ac.ir

Received: 18 June 2008

Accepted: 15 December 2008

hepatomegaly were not found. Physical examination of the abdomen and limbs was normal. Laboratory tests were normal and the hemagglutination test for hydatid cyst was negative.

Chest-x-ray revealed a mass in the middle and upper lobes of the left lung (Figure 1).

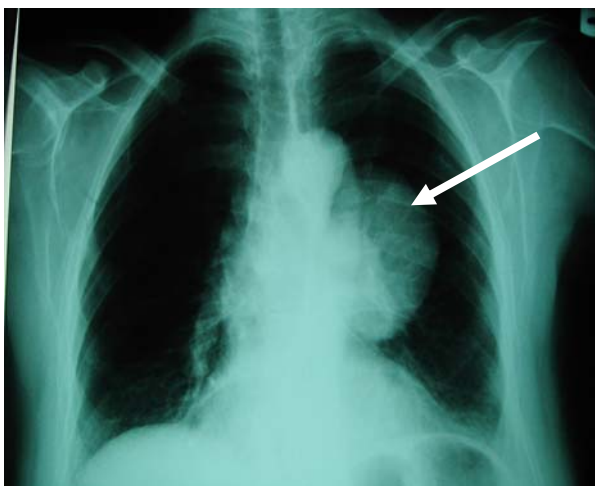


Figure 1. Chest x-ray of the patient showing a mass in the middle zone of the left hemi-thorax (white arrow)

CT-scan of the lungs showed a mass in the left upper parenchymal lobe with a mixed density (-4 to 20 HU) (Figure 2) without airway connection or pleural involvement.

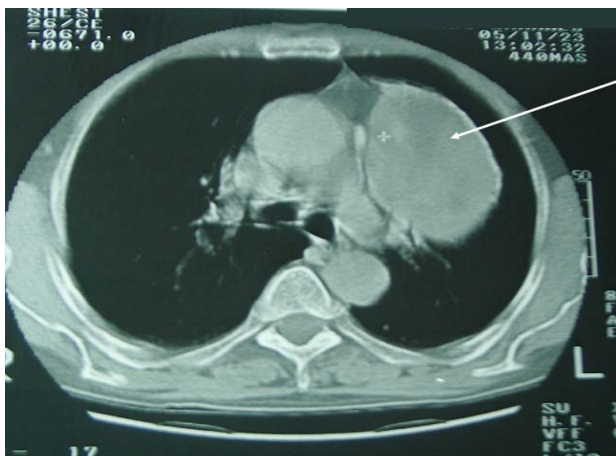

Figure 2. CT-scan demonstrating a mass in the left upper lobe (white arrow)

Fiberoptic bronchoscopy was normal; thus, the patient underwent surgical operation. Cardiac

consultation and pulmonary function tests were also performed in advance.

At the time of operation, a mass was seen in left upper lobe and a piece of the tumor was sent for frozen section. After documentation of malignancy, left upper lobectomy was performed. Mediastinal lymphadenopathy was not present. Figure 3 demonstrates a gross pathological view of the tumor. A very small airway connection was responsible for hemoptysis in the patient.

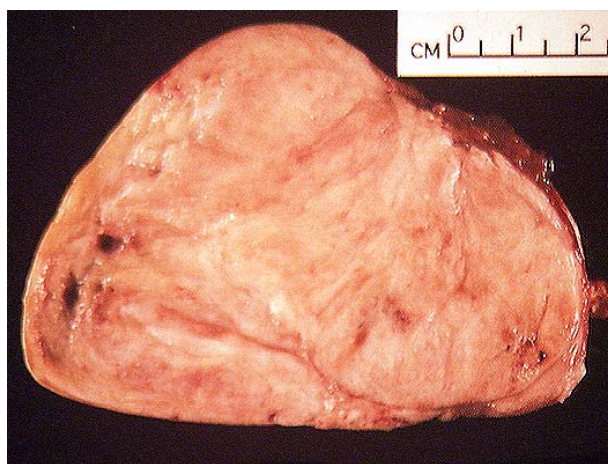


Figure 3- Gross pathology of the tumor

Figure 4 demonstrates a microscopic view of the tumor. The diagnosis was confirmed by immunohistochemistry staining.

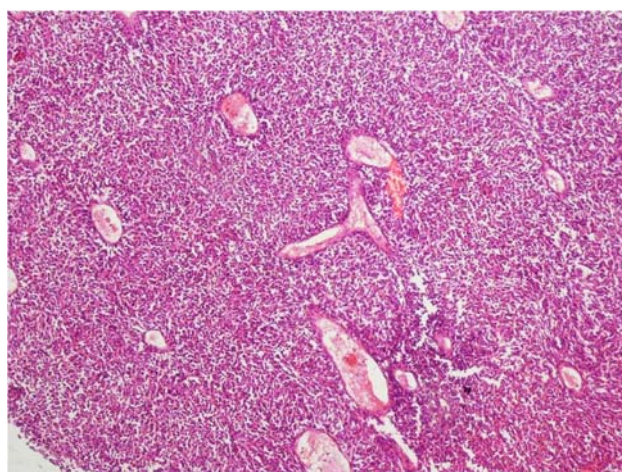


Figure 4. Picture shows a highly cellular mesenchymal tumor with staghorn vessels.

The most common tumor considered in differential diagnosis was solitary fibrous tumor. These two entities can be distinguished principally on the basis of general histopathological features. Therefore, there are no immunohistochemical differences.

In our case, hemangiopericytoma was considered due to the presence of obvious pericytic vascular pattern and fusiform (versus spindle-shaped) tumoral cells,

Synovial sarcoma was also considered in differential diagnosis which was ruled out because of the lack of spindle cells, biphasic and glandular patterns and also negative result for cytokeratin.

There was no island of well differentiated cartilage and also S-100 was negative; therefore, mesenchymal chondrosarcoma was ruled out as well.

Epithelial tumors with sarcomatoid differentiation were ruled out due to the lack of typical epithelial foci, expression of cytokeratin or epithelial membrane antigen (EMA) by tumoral cells.

Microscopic examination revealed highly cellular mesenchymal neoplastic tissue with numerous staghorn vessels. The tumor consisted of fusiform cells with indistinct cytoplasmic border. Mitotic activity was about 1 mitosis/ 10 HPF. There was no evidence of necrosis or hemorrhage. The neoplastic cells were immunoreactive for CD34 and vimentin, but not for cytokeratin, S-100 or desmin (Table 1)

Table 1. Immunohistochemistry staining of the tumor

Markers	Results
Vimentin	Strongly positive
CD 34	Moderately positive
Cytokeratin	Negative
S-100	Negative
Desmin	Negative
EMA	Negative

Figure 5 demonstrates IHC view of microscopic examination with CD34 positive results.

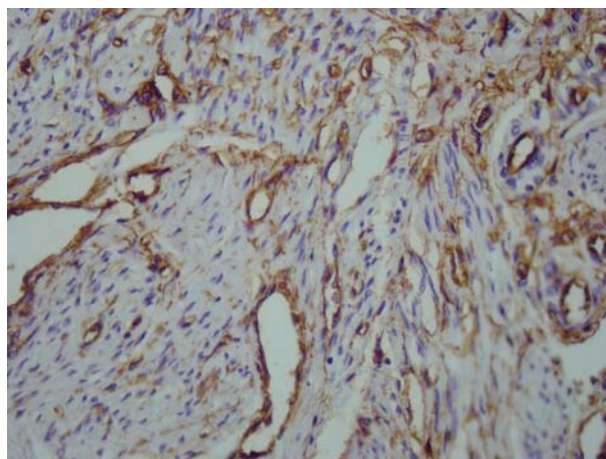


Figure 5. In hemangiopericytoma most tumoral cells express CD34

Figure 6 shows the post-operative chest-x-ray.

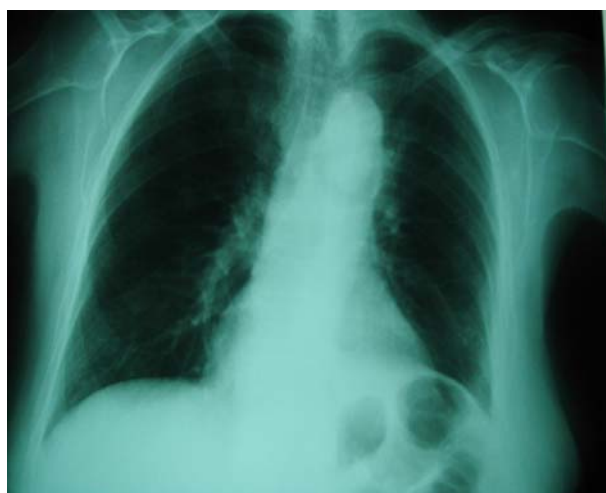


Figure 6. Post-operative CXR of the patient

DISCUSSION

Primary pulmonary hemangiopericytoma (HPC) is a tumor of vascular origin developing from pericytes. It is a very rare occurrence and there is no predilection for any particular lobe. The tumors may be centrally or peripherally located, but many are large when first discovered and their precise site of

origin may be difficult to establish (3,4).

Preoperative diagnosis is difficult. Diagnosis cannot be based solely on clinical symptoms, which often do not exist or on radiological findings, which are of low specificity. The value of CT scan is obviously limited. The course is unpredictable since even histopathological findings fail to provide definitive evidence. In diagnosis of tumors, histopathological examination is very important (5).

HPC was first described and named by Stout and Murray. Diagnosis of HPC has traditionally rested principally on the presence of an architectural pattern, namely an elaborate branching pattern of small and large vessels. This architectural pattern can be seen in a variety of other benign and malignant tumors. Even Stout apparently used this same general approach when he quipped "it has been my general attitude in regard to HPC to reject it as a diagnosis if I can think for any other reasonable explanation for the tumor" (6).

HPC is rapidly becoming nonexistent and a description that HPC is related, if not identical, to solitary fibrous tumor (SFT) is becoming clear (2). The observation that both HPC and SFT express the human progenitor antigen CD34 and can be associated with hypoglycemia forged the link between the two. A new definition might be the following : a tumor that shows a consistent HPC pattern throughout the entire tumor with reticulin surrounding individual cells (everywhere) , and that is negative for muscle, nerve sheath and epithelial markers but positive for CD34 and CD99 (7).

The differential diagnosis includes metastasis from primary extrapulmonary hemangiopericytoma. Other tumors to be considered are primary and metastatic malignant melanoma, other forms of pulmonary sarcoma, carcinoid tumor, chemodectoma, benign clear cell tumor, intrapulmonary localized fibrous tumor and thymoma, both metastatic and primary within the

lungs (8). Special stains, immunohistochemistry and electron microscopy are all helpful in ruling out these other entities. The reticulin pattern is helpful in distinguishing carcinoids and chemodectomas, both of which show distinct packaging of cell groups. Thymomas generally have very sparse reticulin, apart from that around perivascular spaces. The benign clear cell tumor has reticulin fibers around individual cells but lacks a perivascular pattern and contains abundant glycogen. Carcinoid tumors and thymomas express cytokeratin and have ultrastructural features of epithelial tumors, whilst both carcinoid tumors and chemodectomas contain dense-core secretory granules and express neuroendocrine markers. The distinction between hemangiopericytoma and solitary fibrous tumors is perhaps the most difficult and it is likely that some reported cases of the former entity belong to the latter category. The reticulin patterns are similar, both tumors express CD34 and both lack very distinctive ultrastructural features (9).

Treatment is surgical excision. Prognosis is variable. A poor prognosis is usually associated with chest symptoms, tumor greater than 8 cm in diameter, pleural and bronchial wall invasion, tumoral giant cells with more than 3 mitosis per 10 HPFs, and tumor necrosis (10).

Malignancy is usually manifested as intrathoracic recurrence within 2 years of treatment. Distant metastasis occurs in about 22% of patients. The metastases may appear after a disease-free interval of many years. All hemangiopericytomas are therefore to be regarded as potentially malignant and complete resection is the therapy of choice (10). Our patient has had no sign of recurrence or metastasis in 2 years after undergoing operation.

In conclusion, Primary pulmonary hemangiopericytoma does exist, but most cases diagnosed as such are most probably other entities. Radiological findings are not very characteristic. Macroscopic findings mimic hamartoma. However,

in case of hemorrhage in the resection area, primary pulmonary hemangiopericytoma should be considered. Extirpation of these tumors is an effective treatment depending on the location and the extent of the tumor.

REFERENCES

1. Han S, Yazkan R, Cakiroglu E, Sakinci U. Primary pulmonary haemangiopericytoma: a very rare case. *Heart Lung Circ* 2005; 14 (4): 263- 5.
2. Kuroya M, Yokomise H, Inui K, Ike O, Mizuno H, Wada H, et al. Resection of primary pulmonary hemangiopericytoma: a report of two cases. *Surg Today* 1996; 26 (3): 208- 12.
3. Kiefer T, Wertz H, Freudenberg N, Hasse J. Long-term survival after repetitive surgery for malignant hemangiopericytoma of the lung with subsequent systemic metastases: case report and review of the literature. *Thorac Cardiovasc Surg* 1997; 45 (6): 307- 9.
4. Wu YC, Wang LS, Chen W, Fahn HJ, Huang MH, Whang-Peng J. Primary pulmonary malignant hemangiopericytoma associated with coagulopathy. *Ann Thorac Surg* 1997; 64 (3): 841- 3.
5. Razzuk MA, Nassur A, Gradner MA, Martin J, Gohara SF, Urschel HC Jr. Primary pulmonary hemangiopericytoma. *J Thorac Cardiovasc Surg* 1977; 74 (2): 227- 9.
6. Enzinger A, Weiss SW. Perivascular tumor In: Weiss S. W, Goldblum J R. Enzinger and Weiss's Soft tissue tumor 4th ed. New York: Mosby; 2001. p 1001, 1004.
7. Brooks J. Disorder of soft tissue In: Mills S. E. Stenberg diagnostic surgical pathology 4th edition. Philadelphia: Lippincott Williams & Wilkins; 2004, p 190.
8. Hansen CP, Francis D, Bertelsen S. Primary hemangiopericytoma of the lung. Case report. *Scand J Thorac Cardiovasc Surg* 1990; 24 (1): 89- 92.
9. Yousem SA, Hochholzer L. Primary pulmonary hemangiopericytoma. *Cancer* 1987; 59 (3): 549- 55.
10. Van Damme H, Dekoster G, Creemers E, Hermans G, Limet R. Primary pulmonary hemangiopericytoma: early local recurrence after perioperative rupture of the giant tumor mass (two cases). *Surgery* 1990; 108 (1): 105- 9.