

Tanaffos (2009) 8(3), 77-80

©2009 NRITLD, National Research Institute of Tuberculosis and Lung Disease, Iran

A Young Dentist with Fever, Mediastinal Lymphadenopathies and Pulmonary Infiltration

Davood Mansouri^{1,2,3}, Narges Mikaniki¹, Monireh Kamali¹, Ayyub Ghafoorian¹, Majid Marjani¹, Zohreh Mohammad Taheri^{4,5}

¹ Department of Internal Medicine, Division of Infectious Disease and Clinical Immunology, ² Mycobacteriology Research Center, ³ Lung Transplantation Research Center, ⁴ Department of Pathology, Molecular Pathology Section, ⁵ Tracheal Disease Research Center, NRITLD, Shahid Beheshti University MC, TEHRAN- IRAN.

WHAT IS YOUR DIAGNOSIS?

A 40 year-old dentist with no history of disease presented with fever, pleuritic chest pain, cough, myalgia and weight loss (4 kg) from one month before admission. No abnormality was found on physical examination except for expiratory coarse crackles on the base of the right lung. Initial clinical work up showed elevated ESR (ESR=128), positive CRP with hypochromic normocytic anemia (Hemoglobin :12.0 gr/dl MCV=81.6 MCH=25.6 MCHC=30.7), total leukocyte count of 9.900 cell/ μ l with normal differentiation and abnormal liver function tests (mild elevation in ALT:59, AST=31 and Bil total=0.7) with highly elevated ALP :477. Other biochemistry and electrolytes tests were normal. Anti-nuclear antibody(ANA), anti-dsDNA, antineutrophil cytoplasmic antibody (C,P-ANCA), rheumatoid factor (RF), Wright, Coombs Wright and serologic studies for HIV, HCV and HBV as well as the PPD test were all negative. Sputum smear and PCR for acid fast bacilli and culture for routine bacteriology were negative. Chest-x ray (Figure 1), lung CT-scan (Figure 2) and bronchoscopy were also performed. (*Tanaffos* 2009; 8(3): 77-80)

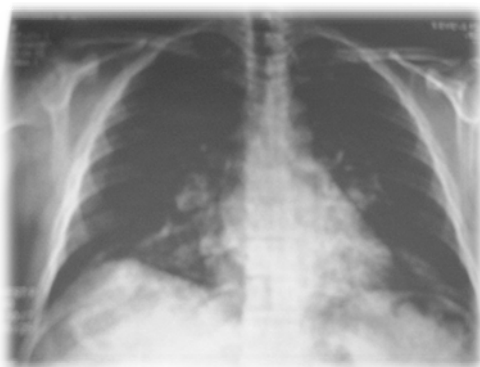


Figure 1. Bilateral lymphadenopathy

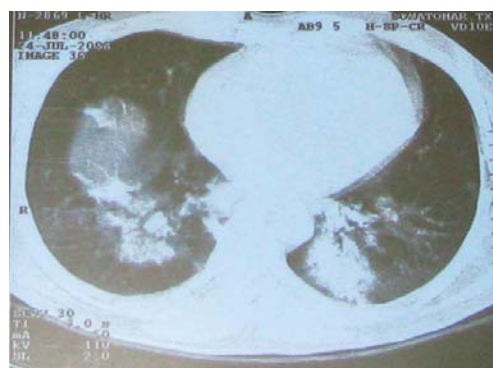


Figure 2. Parenchymal infiltration and bilateral lymphadenopathy

Correspondence to: Mansouri D

Address: NRITLD, Shaheed Bahonar Ave, Darabad, TEHRAN 19569, P.O:19575/154, IRAN

Email address: dmansouree@yahoo.com

Diagnosis: Pulmonary Sarcoidosis with Organizing Pneumonia

Chest x-ray and lung CT-scan demonstrated multiple bilateral mediastinal lymphadenopathies and parenchymal alveolar infiltrations. Bronchoalveolar lavage (BAL) specimen revealed numerous ciliated columnar cells, macrophages and PMNs. Histopathology of the lung specimen obtained by transbronchial lung biopsy (TBLB) revealed organizing pneumonia and granulomatous reaction (Figure 3). The angiotensin converting enzyme (ACE) level was 111 (normal up to 52). Prednisolone 30 mg daily was started and tapered during the next 10 months to 2.5mg daily. The patient responded well to the treatment and became symptom-free. Laboratory tests (ACE=43, ALP=99 and ESR=17) and radiographic findings (Figure 4) returned to normal as well.

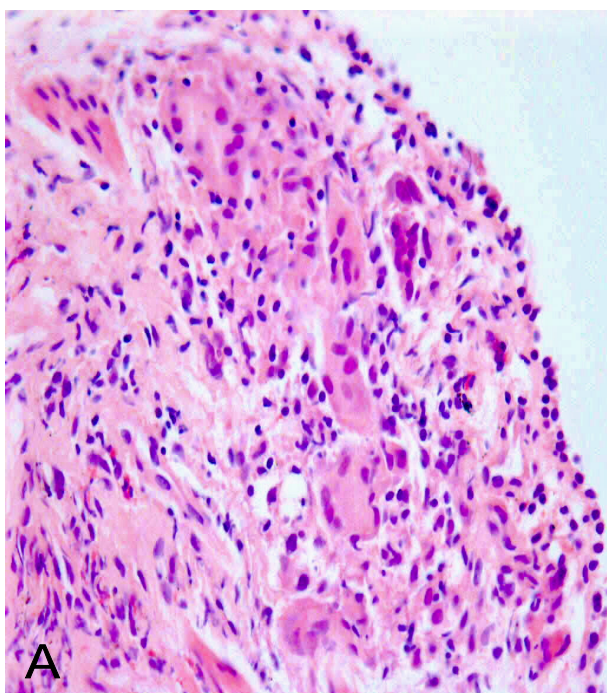
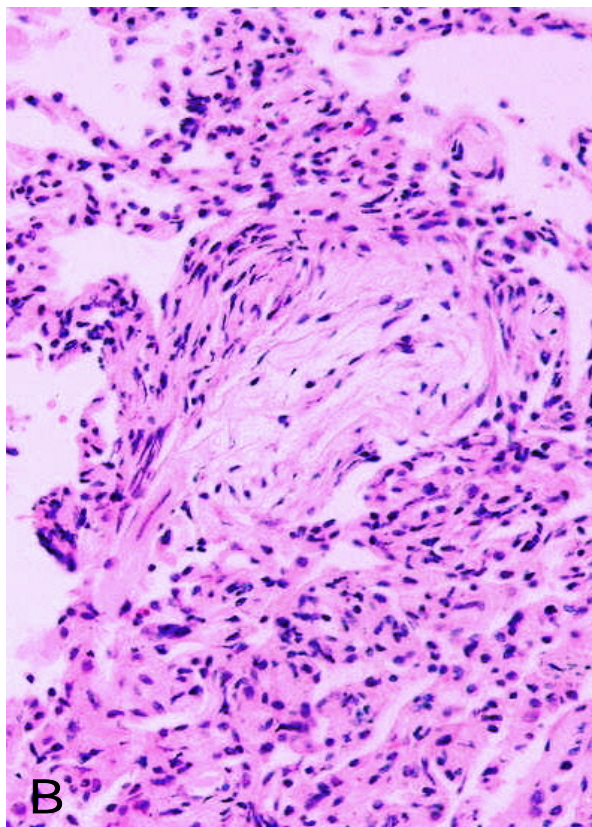


Figure 3. TBLB (A) Patchy areas of intra-alveolar Masson bodies with extension into the alveolar duct as well as interstitial widening due to inflammatory cells, infiltrations of lymphocytes, histiocytes, some eosinophils, type 2 pneumocytes hyperplasia and intra-alveolar lipid macrophages as well as multinucleated giant cells.



(B) One focus of loose noncaseating granuloma consisting of epithelioid cells, histiocytes and multinucleated giant cells in peribronchial region.

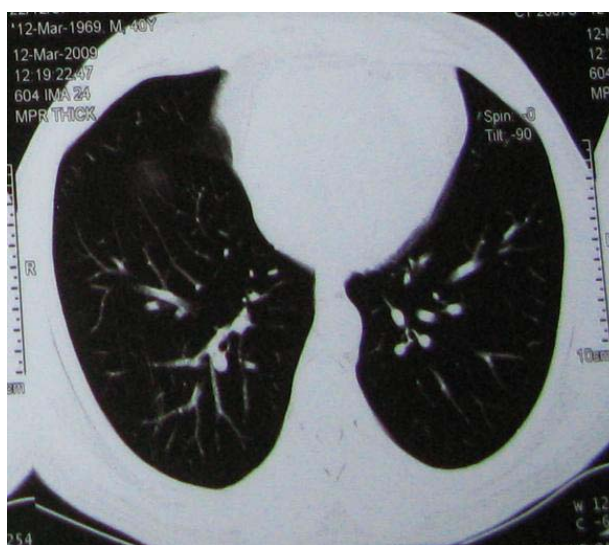


Figure 4. Lung CT-scan (with contrast) 10 months after treatment

Organizing pneumonia is characterized by the presence of granulation tissue in the distal air spaces. When organizing pneumonia is associated with granulation tissue in the bronchiolar lumen, the qualifying term bronchiolitis obliterans (BO) is added. Bronchiolitis Obliterans with Organizing Pneumonia (BOOP) is a distinct clinicopathological entity with clinical, imaging and prognostic features. Persons of all ages can be affected (1). BOOP should be considered when multiple large nodular lesions have chest CT findings of air bronchogram, irregular margins, broad pleural tags, parenchymal bands or subpleural lines (2,3).

Distinguishing sarcoidosis from BOOP can be difficult. Sarcoidosis usually occurs in 20 to 50 year-old patients. BOOP occurs more frequently in 50 to 60 year-old patients. Both entities may be characterized by fever, night sweat, malaise, weight loss, and dyspnea (4,5). Symmetric peripheral opacities and bulky hilar or mediastinal adenopathy on plain chest radiographs strongly suggest a diagnosis of sarcoidosis. Pulmonary opacities occur in 25 to 50% of sarcoidosis patients, typically involving the medial aspect of the mid and upper lung zones. Bilateral peripheral opacities rarely occur in sarcoidosis. Large thoracic adenopathy is not characteristic of BOOP (4). The histological appearance of BOOP and sarcoidosis differ as mononuclear cells and Langerhans giant cell granulomas characterize the acinar infiltrates of sarcoidosis; whereas, BOOP is characterized by fibroblasts, myofibroblasts, and granulation buds in the distal airways and alveoli. The BAL cell counts reflect these different underlying histologies: mononuclear cells in sarcoidosis, and mixed cell populations with modestly increased lymphocyte numbers in BOOP (5, 6).

In this case, bilateral peripheral radiographic opacities, bulky hilar and mediastinal adenopathy, highly elevated ACE level and Alkaline phosphatase, all suggested the diagnosis of sarcoidosis not BOOP. On the other hand, histologic examination demonstrated a mixed cell pattern, patchy areas of intra-alveolar Masson bodies with extension into the alveolar duct, interstitial widening due to inflammatory cells, infiltrations of lymphocytes, histiocytes, some eosinophils, type 2 pneumocytes hyperplasia, intra-alveolar lipid macrophages and multinucleated giant cells. One focus of loose noncaseating granuloma consisting of epithelioid cells, histiocytes and multinucleated giant cells in peribronchial region with negative special stains and cultures for mycobacteria and fungal agents established the diagnosis of organizing pneumonia and sarcoidosis. Ultimately, the dramatic response to steroids supported the diagnosis of BOOP.

In conclusion, we believe this patient had sarcoidosis with BOOP reaction. To our knowledge, this is the first case of sarcoidosis presenting with organizing pneumonia. Bronchiolitis obliterans-organizing pneumonia (BOOP), now referred to as cryptogenic organizing pneumonia (COP) can rarely mimic sarcoidosis clinically and radiologically. Therefore, it is suggested that this entity be included in the differential diagnosis of hilar and mediastinal lymphadenopathies.

REFERENCES

1. Sara AG, Hamdan AJ, Hanaa B, Nawaz KA. Bronchiolitis obliterans organizing pneumonia: Pathogenesis, clinical features, imaging and therapy review. *Ann Thorac Med* 2008; 3 (2): 67- 75.
2. Bouchardy LM, Kuhlman JE, Ball WC Jr, Hruban RH, Askin FB, Siegelman SS. CT findings in bronchiolitis obliterans

- organizing pneumonia (BOOP) with radiographic, clinical, and histologic correlation. *J Comput Assist Tomogr* 1993; 17 (3): 352- 7.
3. Polverosi R, Maffesanti M, Dalpiaz G. Organizing pneumonia: typical and atypical HRCT patterns. *Radiol Med* 2006; 111 (2): 202- 12.
 4. Lee FE, Caracta CF, Fine A, Berk JL. Fevers, weight loss, and bilateral peripheral infiltrates in a young man. *Chest* 1999; 115 (4): 1181- 3.
 5. Rodríguez E, López D, Bugés J, Torres M. Sarcoidosis-associated bronchiolitis obliterans organizing pneumonia. *Arch Intern Med* 2001; 161 (17): 2148- 9.
 6. Alsaghir AH, Al-Mobeireek AF, Al-Jahdali H, Al-Eithan A, Al-Otair H, Al-Dayel F. Bronchiolitis obliterans organizing pneumonia: experience at three hospitals in Riyadh. *Ann Saudi Med* 2007; 27 (1): 32- 5.