

Tanaffos (2011) 10(1), 57-59

©2011 NRITLD, National Research Institute of Tuberculosis and Lung Disease, Iran

A 29 Year-Old Woman with Cough and Dyspnea

Ilad Alavi Darazam¹, Mihan Pourabdollah², Shahram Kakhui³, Neguine Rezaii¹, Davood Mansouri¹

¹ Clinical Tuberculosis and Epidemiology Research Center, ² Department of Pathology ³ Chronic Respiratory Disease Research Center, NRITLD, Shahid Beheshti University of Medical Sciences, TEHRAN-IRAN.

WHAT IS YOUR DIAGNOSIS?

A 29-year-old woman was admitted due to persistent dry cough and dyspnea worsening nocturnally. She was exposed to stimulants for the last five months. She mentioned a contact with a pigeon before the development of her pulmonary manifestations. She was divorced, without any children, had an office work and smoked less than 2 cigarettes a day. In the following months the patient had out-patient visits and received antitussive and anti-allergic drugs and occasionally antibiotics which did not improve her symptoms. Eventually, after about 4 months and emergence of mild constitutional symptoms she was admitted to the Pulmonary Department and diagnostic tests were performed along with imaging studies (Figure 1). She had normal routine laboratory tests and normal bronchoscopy. Transbronchial lung biopsy showed chronic non-specific inflammation. The patient did not consent to open lung biopsy that was recommended to her. Therefore, with the possible diagnosis of hypersensitive pneumonia, 50 mg prednisolone daily was started for her. After about 2 weeks she stopped taking medications and admitted to our center. At the time of admission the patient was conscious and did not look very ill. But her dry coughs were so continual that she could not utter a complete sentence without interruption. Her vital signs were blood pressure: 110/70 mmHg, pulse rate: 88/ minute, respiratory rate: 24/minute, body temperature: 36.9°C and oxygen saturation in ambient air: 95%. Physical examination revealed a 2 cm firm fixed mass in her right submandibular angle. The patient claimed that the mass has been present there for years but it was smaller and mobile. Pulmonary fields were clear without wheezing or crackle. Other examinations were unremarkable. Complete blood cell count showed mild leukocytosis with other indices within the normal range. Erythrocytes sedimentation rate was 40 mm/min. Arterial blood gas analysis showed pH of 7.37, PCO₂: 37.6 mmHg and HCO₃: 21meq/L. Biochemical tests including renal and hepatic function tests, lactate dehydrogenase and creatine kinase were normal. Rheumatologic evaluation was unremarkable with angiotensin converting enzyme 38U/L (normal). Imaging studies were performed in this center (Figure 2). The cervical mass was totally excised and sent for pathologic examination. The sample was a mass of 3 cm in size with an intact capsule and the surrounding adhesions. Half of it was sent for culture. The pathologic report was pleomorphic adenoma of the salivary gland. Culture was unremarkable. Finally bronchoscopy and transbronchial lung biopsy were performed. (*Tanaffos* 2011; 10(1): 57-59)

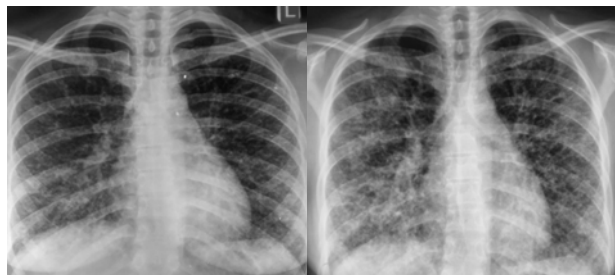


Figure 1.. Chest x ray in the left, 4 months before admission and the right on admission

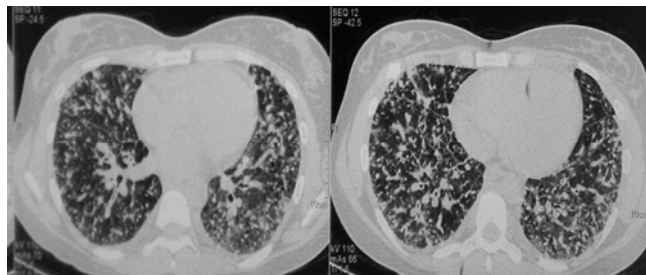


Figure 2.. HRCT of lung on admission

Correspondence to: Mansouri D

Address: NRITLD, Shaheed Bahonar Ave, Darabad, Tehran 19569, P.O:19575/154, IRAN

Email address: dmansouree@yahoo.com

Diagnosis: Metastatic Lung Adenocarcinoma with Ovarian Origin

Progressive clinical findings particularly progressive cough and dyspnea urged us to re-evaluate the patient's history, physical exam and imaging studies. High resolution computed tomography in this center revealed diffuse bilateral and symmetric interstitial infiltration, thickening and scattered nodules of lungs and hilar and mediastinal calcified nodules.

Abdominopelvic CT-scan reported lytic lesion of a right rib and pleural thickening, a mass of soft tissue in right adnexa with calcification, free pelvic fluid and severe right hydronephrosis. In abdominopelvic ultrasonography no free fluid but a 5x5 cm mass with cystic and calcified components of right adnexal origin was detected. A left hemorrhagic cyst was another remarkable finding.

The patient underwent another bronchoscopy and histopathologic examination of the lung tissue obtained by transbronchial lung biopsy demonstrated adenocarcinoma (either primary or secondary). Female genital tumor markers were reported as human chorionic gonadotropin: 3 IU/ml, Alpha fetoprotein: 2.1 IU/ml, carcinoembryonic antigen: 2.2 ng/ml and CA125: 49 U/ml.

Sharp multiple nodular infiltrations in the lungs can be seen with Langerhans cell histiocytosis, silicosis, metastatic disease, miliary tuberculosis and disseminated fungal disease (1). But according to the distribution of nodules, perilymphatic, perivascular, centrilobular and airspace involvement, differential diagnosis can be distinguished. Perivascular nodules are the result of hematogenous dissemination, and are characteristically found in miliary tuberculosis (TB), miliary fungal disease, and metastatic spread of tumor (1). History of pulmonary manifestations for several months and diffuse infiltration make miliary

TB and fungal infection very unusual.

Clinical manifestations after contact with a bird had misled to diagnosis of hypersensitive pneumonia (HP) for several months and corticosteroid therapy was administered without confirmation. Hypersensitivity pneumonitis (HP) refers to a group of pulmonary disorders caused by inhalation of organic or inorganic particulates by sensitized persons. The diagnosis relies on a constellation of findings: exposure to an offending antigen, characteristic signs and symptoms, abnormal chest findings on physical examination, and abnormalities on pulmonary function tests and radiographic evaluation (2).

HRCT is increasingly used in the diagnosis of HP (3). Although the HRCT pattern is variable depending on the stage of disease, the characteristic appearance is a mid-to-upper zone predominance of centrilobular ground-glass or nodular opacities with signs of air-trapping (2).

The diagnosis of infiltrative diffuse lung disease may require invasive procedures after all noninvasive tools have failed. The clinical context in which these diseases develop and the radiological patterns are crucial for defining the timing and the methods to be used (4).

Bronchoalveolar lavage is the most important invasive procedure allowing the identification of infectious agents, neoplastic elements and characteristic cytological and phenotypical profiles in the majority of cases. Less frequently, transbronchial lung biopsy, transbronchial needle aspiration and biopsy or surgical lung biopsy are necessary (4).

The patient was referred to oncology service for chemotherapy and she was doing well in her 2 month follow up.

REFERENCES

1. Swensen SJ, Viggiano RW, Midthun DE, Muller NL, Sherrick A, Yamashita K, Naidich DP, Patz EF, Hartman TE, Muhm JR, Weaver AL. Lung nodule enhancement at CT: multicenter study. *Radiology* 2000; 214 (1): 73- 80.
2. Lynch DA, Rose CS, Way D, King TE Jr. Hypersensitivity pneumonitis: sensitivity of high-resolution CT in a population-based study. *Am J Roentgenol* 1992; 159 (3): 469- 72.
3. Lacasse Y, Selman M, Costabel U, Dalphin JC, Ando M, Morell F, et al. Clinical diagnosis of hypersensitivity pneumonitis. *Am J Respir Crit Care Med* 2003; 168 (8): 952- 8.
4. Poletti V, Chilosi M, Olivieri D. Diagnostic invasive procedures in diffuse infiltrative lung diseases. *Respiration* 2004; 71 (2): 107- 19.