

Photo Quiz

©2012 NRITLD, *National Research Institute of Tuberculosis and Lung Disease, Iran*

ISSN: 1735-0344 *Tanaffos 2012; 11(3):55-57*

TANAFFOS 

A 31-Year-Old Female with an Acute Episode of Cough and Hemoptysis

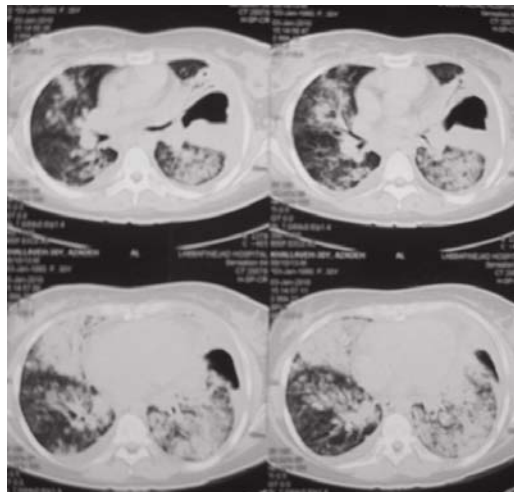
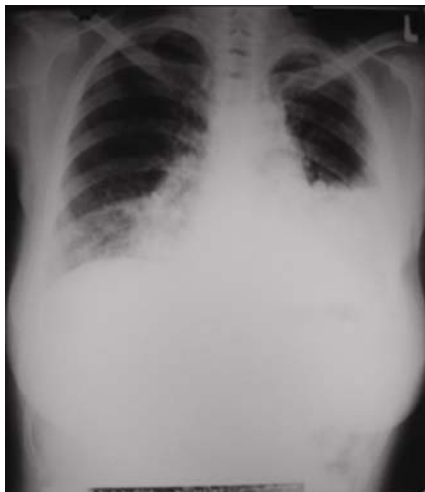Guitti Pourdowlat¹, **Abbas Fadaei**²,
Shahram Kahkouee¹

¹ Chronic Respiratory Diseases Research Center ,
National Research Institute of Tuberculosis and Lung
Diseases (NRITLD), Shahid Beheshti University of
Medical Sciences, Tehran- Iran, ² Pulmonology
Department, Labbafi Nejad Hospital, Shahid
Beheshti University of Medical Sciences, Tehran,
Iran.

WHAT IS YOUR DIAGNOSIS?

A 31 year-old female was admitted to the hospital with an acute episode of cough and hemoptysis, along with low grade fever. She was nonsmoker without any previous history of respiratory symptoms. Laboratory findings showed WBC count 12,200, NEUT: 74%, LYM: 21%, and EOS: 5%.

Correspondence to: Pourdowlat G
Address: NRITLD, Shaheed Bahonar Ave,
Darabad, TEHRAN 19569, P.O:19575/154, IRAN
Email address: purdowlat_g@yahoo.com



Figures 1 and 2. Show the CXR and chest CT of the patient.

Answer

Diagnosis: Ruptured hydatid cyst and defuse pneumonitis

Chest X-ray (Fig.1) shows a homogeneous opacity in lower half of the left hemithorax with a wavy appearance in the upper border, silhouetting left heart border. There are also alveolar shadows in right paracardiac region. Chest CT (Fig.2) reveals cavitory consolidation in left upper lobe (LUL) with internal floating membrane mimicking 'water lily'. Scattered bilateral alveolar opacities are also seen.

At bronchoscopy, a shiny membranous tissue was seen in the lumen of LUL bronchus, suggesting a ruptured hydatid cyst (Fig. 3). Because of pulmonary infiltration, TBLB was done, and pathological findings included lymphocytic and neutrophilic infiltration in the interstitium and alveolar space due to pneumonitis. Smear of bronchoalveolar lavage did not show hooklets and culture was negative for bacteriology. Serologic tests for hydatid cyst were positive. Surgery was performed, and a large hydatid cyst was resected (Fig 4). Parenchymal infiltration resolved subsequently.

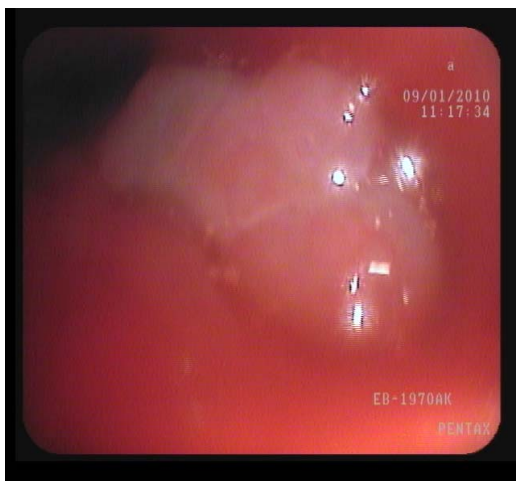


Figure 3. Bronchoscopic appearance of shiny membranous tissue in the lumen of left upper bronchus suggesting ruptured hydatid cyst membrane

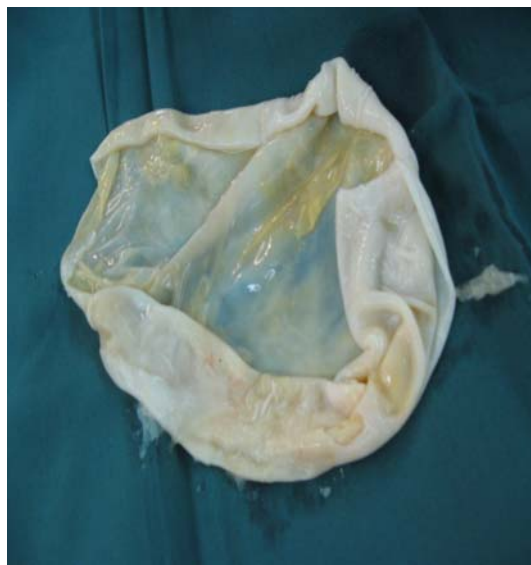

Figure 4. The large hydatid cyst was surgically removed.

DISCUSSION

Hydatid cyst disease is a parasitic infection and one of the important public health problems in endemic areas like Iran. Liver is a common site of hydatidosis. Pulmonary involvement is less common, and comprises about 25 % of patients with hydatid cyst disease (1, 2). Chest x ray is the most valuable diagnostic method for pulmonary hydatid cyst. The typical findings for uncomplicated hydatid cyst are homogeneous round masses with smooth borders that may cause parenchymal atelectasis and pleural reaction (3). Occasionally, in ruptured cysts, 'Cumbo-sign' and 'onion peel' may be seen when air invades between the pericyst and the endocyst (4). Calcification of hepatic cysts is common, while pulmonary cysts are rarely calcified (3).

Some conditions such as benign tumors, carcinomas, metastasis, inflammatory masses, fluid-filled cysts and abscess can mimic the radiologic features of pulmonary

hydatid cyst. CT scan reveals the cystic nature of the masses, and lesions are localized for surgery guidance.

'Inverse crescent sign' is a new terminology for the separation of membranes from the posterior aspect of the cyst by air dissection without any anterior extension (5).

Although transient and local parenchymal infiltration after pulmonary hydatid cyst rupture is common, presentation with diffuse pulmonary infiltration is rare. Bacterial super-infection of the cyst is the most serious complication commonly seen after cyst rupture; but in our patient bronchoalveolar lavage for microorganisms was negative which highly suggests a chemical pneumonitis caused by hydatid cyst rupture. In endemic areas like Iran, familiarity with rare and unusual imaging manifestations of pulmonary hydatidosis, such as diffuse alveolar

shadows and cavitory consolidations is essential for early diagnosis.

REFERENCES

1. Madan K, Singh N. Bronchoscopic diagnosis of pulmonary hydatid cyst. *CMAJ* 2012; 184 (2).
2. Yilmaz A, Tuncer LY, Damadoglu E, Sulu E, Takir HB, Selvi UB. Pulmonary hydatid disease diagnosed by bronchoscopy: a report of three cases. *Respirology* 2009; 14; 141-3.
3. Morar R, Feldman C. Pulmonary echinococcosis. *ERJ* 2003; 21(6): 169-77.
4. Baeyens P, Weynand B, Coche E. Ruptured pulmonary hydatid cyst. *JBR-BTR* 2005; 88; 42.
5. A. Koul P, Ajaz N, Wahid A, A. Mir F. CT in pulmonary hydatid disease. *Chest* 2000; 118: 1645-7.