

# A 60 Year-Old Man with AIDS and Pneumonia

Payam Tabarsi<sup>1,2</sup>, Amir Yousefzadeh<sup>1</sup>,  
Atosa Dorudinia<sup>3</sup>, Majid Marjani<sup>1</sup>, Afshin  
Moniri<sup>1</sup>, Seyed Alireza Nadji<sup>3</sup>, Parvaneh  
Baghaei<sup>1</sup>, Sayena Jabbedari<sup>1</sup>, Davood  
Mansouri<sup>1</sup>

<sup>1</sup> Clinical Tuberculosis and Epidemiology Research Center, National Research Institute of Tuberculosis and Lung Disease, Masih Daneshvari Hospital, Shahid Beheshti University of Medical Sciences, Tehran, Iran, <sup>2</sup> Mycobacteriology Research Center, National Research Institute of Tuberculosis and Lung Disease, Masih Daneshvari Hospital, Shahid Beheshti University of Medical Sciences, Tehran, Iran, <sup>3</sup> Virology Research Center, National Research Institute of Tuberculosis and Lung Disease, Masih Daneshvari Hospital, Shahid Beheshti University of Medical Sciences, Tehran, Iran

Correspondence to: Tabarsi P

Address: NRITLD, Shaheed Bahonar Ave,  
Darabad, TEHRAN 19569, P.O:19575/154, IRAN  
Email address: payamtabarsi@yahoo.com

## WHAT IS YOUR DIAGNOSIS?

A 60 year-old man was admitted to our hospital with a four-week history of fever, non-productive cough and progressive dyspnea. He had been diagnosed with pneumonia in another hospital and had received broad-spectrum antibiotics including ceftriaxone, azithromycin and vancomycin with no improvement. The patient was referred to our hospital. On admission, the patient's body temperature was 38.1°C, blood pressure was 95/50 mm Hg, pulse rate was 106 beats/min, respiratory rate was 27/min and percutaneous oxygen saturation was 78% in room air. Pulmonary auscultation revealed fine crackles over the lung bases. Intraoral candidiasis was also seen. Physical examination was otherwise normal. The patient's white blood count was 2,600 cells/mm<sup>3</sup> (Lymphocytes = 26%, neutrophils =70%) and the HIV ELISA test turned out to be positive which was confirmed by western blot assay. Laboratory investigations also revealed a low CD4+ cell count (72 cells/  $\mu$ l), normal liver function, negative blood culture and three negative AFB sputum smear results. The PCR test performed on his nasopharyngeal swab was negative for both influenza A and influenza H1N1 virus. His chest radiograph and chest CT are shown in Figures 1 and 2.

Fiberoptic Bronchoscopy was normal. Transbronchial biopsy is shown in Figure 3.

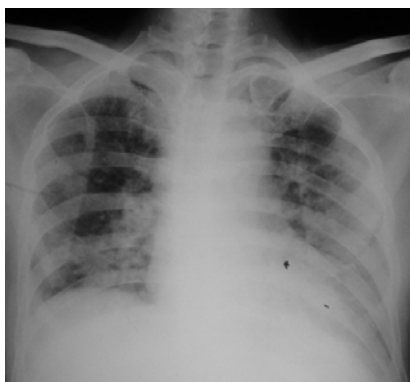

Figure 1. Chest x ray of patient.

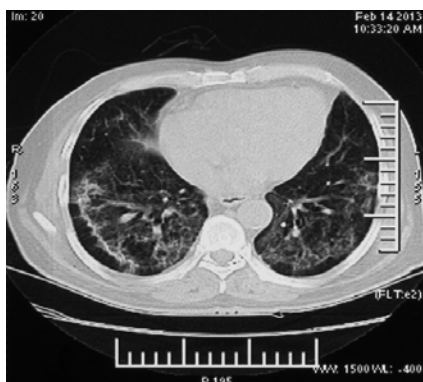

Figure 2. Chest CT-scan of patient.

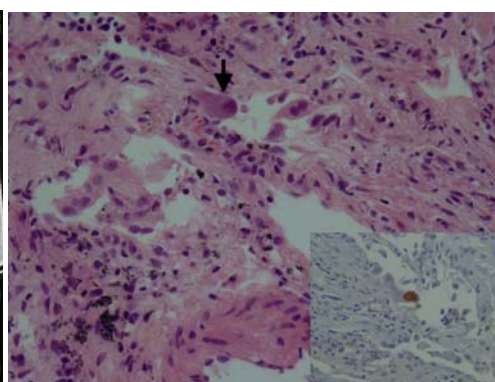


Figure 3. Histological specimen of transbronchial biopsy.

## Answer

### Diagnosis: CMV Pneumonitis

On TBLB, there was moderate inflammatory infiltrate rich in lymphocytes accompanied by large cells with large nuclei, intracytoplasmic and intranuclear inclusions and perinuclear halo with owl's eye pattern. On immunohistochemistry reaction (IHC), described cells were stained with CMV Ab. The CMV PCR test on both plasma and bronchoalveolar lavage (BAL) specimens was positive. No other pathogen including bacteria, mycobacteria or fungi were cultured from the samples obtained from bronchoalveolar lavage (BAL) and from pulmonary tissue. Additionally, BAL fluid staining with monoclonal antibodies for *Pneumocystis jirovecii* was negative.

The patient was diagnosed with CMV pneumonia and AIDS. Intravenous ganciclovir was administered at a dose of 5 mg/kg every 12 hours for three weeks along with antiretroviral therapy (zidovudine, lamivudine and efavirenz). The symptoms improved within 20 days and the plasma CMV PCR test changed to negative. Chest radiography also showed remarkable improvements. The patient received 900 mg of Valganciclovir twice daily for the next three weeks and continued to take Valganciclovir 900 mg once daily for maintenance treatment. Currently, he is reported to be entirely recovered from pneumonia.

Radiologic findings in CMV pneumonia usually include bilateral interstitial or reticulo-nodular infiltrates which begin at the periphery of the lower lobes and spread centrally and superiorly (1). Such nonspecific findings make the diagnosis of CMV pneumonitis in patients with advanced HIV infection exceedingly difficult. Although CMV has been detected in 19% to 74% of pulmonary secretions of HIV-positive patients undergoing bronchoscopic examination for pulmonary evaluation, this virus is rarely confirmed as the sole pathogen in HIV-

infected patients with pneumonia (1, 2). In fact, the virus may be cultured from BAL fluid specimen of healthy and immunocompromised patients in absence of histologic evidence of CMV pneumonia which is usually needed to establish the definitive diagnosis (2). While the finding of a positive culture or PCR for CMV does not confirm a diagnosis of CMV pneumonia, a positive test should not be readily assumed to be "shedding," and there is evidence that CMV pneumonia in HIV patients is underdiagnosed. Postmortem examination of 25 consecutive patients who had died of AIDS revealed CMV pneumonia in 8 (32%) cases (3). In another study of 210 consecutive HIV-infected patients undergoing lung biopsy, 50% were culture-positive for CMV, while 8% had culture and histology consistent with CMV pneumonia (2). CMV pneumonia should be considered in all HIV- infected patients with CD4+ cell counts of <100 and pulmonary infiltrates of unknown origin.

### REFERENCES

1. Herry I, Cadranel J, Antoine M, Meharzi J, Michelson S, Parrot A, et al. Cytomegalovirus-induced alveolar hemorrhage in patients with AIDS: a new clinical entity? *Clin Infect Dis* 1996; 22 (4): 616- 20.
2. Rodriguez-Barradas MC, Stool E, Musher DM, Gathe J Jr, Goldstein J, Genta RM, et al. Diagnosing and treating cytomegalovirus pneumonia in patients with AIDS. *Clin Infect Dis* 1996; 23 (1): 76- 81.
3. Dore GJ, Marriott DJ, Duflo JA. Clinico-pathological study of cytomegalovirus (CMV) in AIDS autopsies: under-recognition of CMV pneumonitis and CMV adrenalitis. *Aust N Z J Med* 1995; 25 (5): 503- 6.