

# Acremonium Pneumonia: Case Report and Literature Review

Atefeh Fakharian <sup>1</sup>, Atosa Dorudinia <sup>2</sup>, Ilad Alavi Darazam <sup>1</sup>, Davood Mansouri <sup>3</sup>, Mohammad Reza Masjedi <sup>1</sup>

<sup>1</sup> Chronic Respiratory Diseases Research Center, National Research Institute of Tuberculosis and Lung Diseases (NRITLD), Shahid Beheshti University of Medical Sciences, Tehran, Iran, <sup>2</sup> Tracheal Diseases Research Center, NRITLD, Shahid Beheshti University of Medical Sciences, Tehran, Iran, <sup>3</sup> Clinical Tuberculosis and Epidemiology Research Center, NRITLD, Shahid Beheshti University of Medical Sciences, Tehran, Iran.

Received: 7 November 2014

Accepted: 20 Jan 2015

Correspondence to: Alavi Darazam I

Address: National Research Institute of Tuberculosis and Lung Diseases, Shahid Beheshti University of Medical Sciences, Tehran, Iran

Email address: ilad13@yahoo.com

## INTRODUCTION

*Acremonium* formerly known as *cephalosporium*, is recognized as a causative agent of human skin infections (1). Eumycotic mycetoma- mycetoma due to fungi- is caused by a variety of fungi but not commonly by *Acremonium* (2). Moreover, the most common pathogens of onychomycosis (fungal infection of nails) are dermatophytes and *Fusarium* spp. followed by *Acremonium* spp. (3).

Several cases of ocular infections particularly keratitis have been published in the literature (4).

Localized infections (other than skin, nail and eyes) and systemic involvement due to *Acremonium* spp. are not common and have been reported in case reports.

Pneumonia and disseminated infections including meningitis, endocarditis, and cerebritis have been rarely

*Acremonium* spp. cause human superficial infections including mycetoma, onychomycosis and keratitis. There are a few reports of systemic involvement in immunocompromised patients. However, isolated pulmonary infection in otherwise healthy hosts has never been reported in the literature.

Herein, we report a 59 year-old diabetic man with non-resolving pneumonia due to *Acremonium* spp. and provide a consensus review of the published clinical cases of systemic and respiratory tract infections.

**Key words:** Acremonium, Pneumonia, Diabetes, Immunocompromised host, Systemic infection

reported. The reports of systemic infections, particularly pulmonary diseases, are almost always in patients with underlying risk factors such as malignancies and transplantation (1). Literature reviews revealed no case of pulmonary disease in otherwise healthy patients.

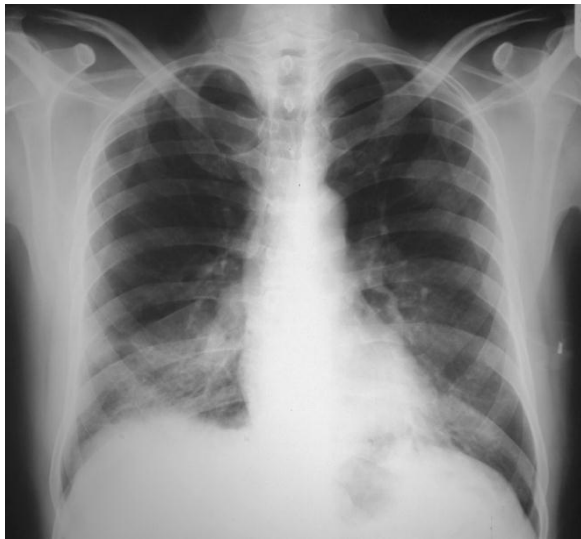We report an unusual case of pulmonary infection due to *Acremonium* in a diabetic man who was properly treated with itraconazole.

## CASE SUMMARIES

A 59 year-old man was admitted with complaints of productive cough and dyspnea. He was healthy until approximately 2 months earlier when he experienced fever, chills and productive cough during a trip to the north of Iran. Non-massive hemoptysis occurred soon after

initial presentation. His symptoms worsened despite outpatient management of pneumonia with ceftriaxone and azithromycin. He also developed night sweat and purulent sputum.

Due to progressive symptoms and significant weight loss as well as chest imaging findings (Figure 1), bronchoscopy was performed without remarkable findings. Due to antibiotic treatment failure, he had been treated with standard anti-tuberculosis regimen for 6 weeks in another center without any response.



**Figure 1.** The left chest-X-ray revealed alveolar infiltration in the right lower lobe before diagnosis.

He lived with his wife and three healthy children and worked as a manager of a service company. He reported smoking 3 cigarettes per day since 20 years ago and occasionally inhaled opiates. He was diabetic since 19 years ago controlled with oral medications. He was otherwise healthy. He did not recall any contact with birds and animals nor with chemical agents.

On admission, he was febrile (38.5°C oral temperature) and normotensive with a respiratory rate of 20 breaths/minute and oxygen saturation rate of 91% with ambient air.

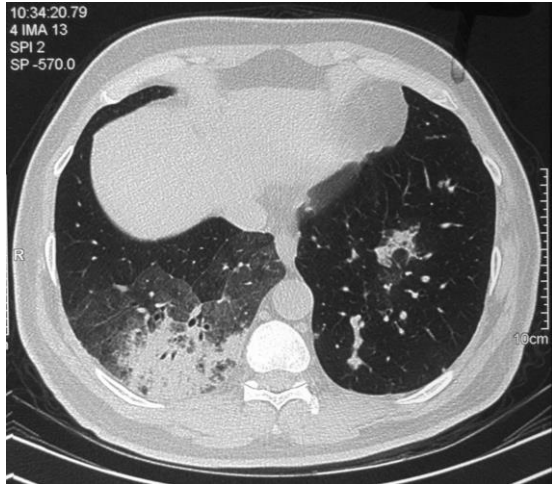Physical examination was normal except for pallor of conjunctiva.

Further investigations revealed normochromic normocytic anemia (hemoglobin 9.5 mg/dl), leukocytosis (12400 cells/mm<sup>3</sup>, polymorphonuclears: 76%, eosinophils: 4%), thrombocytosis (536,000/mm<sup>3</sup>), elevated erythrocyte sedimentation rate (130 mm/1<sup>st</sup> hr.), normal liver biochemistry and renal function tests. Urinalysis was normal. Antinuclear antibodies (ANA) and antineutrophil cytoplasmic antibodies (ANCA) were negative. Glycosylated hemoglobin (HbA1C) and fasting plasma glucose (FPG) were 6.9% and 115 mg/dl, respectively. Level of immunoglobulins and lymphocytes, flow cytometric analysis and nitroblue tetrazolium test as well as human immune deficiency virus serology were unremarkable. Moreover, scar of the bacille Calmette-Guérin (BCG) vaccine was evident.

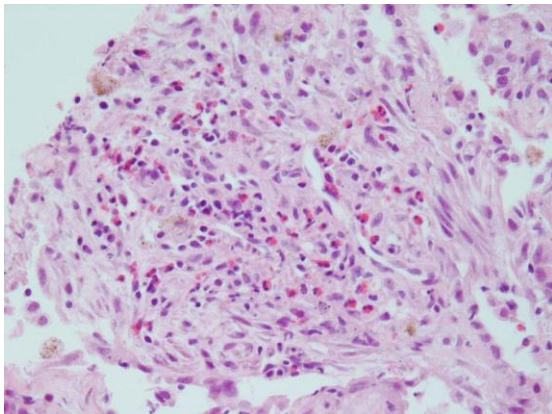
Echocardiography was normal. Repeated bronchoscopy in our center revealed mucosal secretion without endobronchial lesion. Transbronchial lung biopsy as well as bronchoalveolar lavage specimens were negative for pathogenic bacteria, fungi and mycobacterial agents by smears, cultures and polymerase chain reaction.

Based on his progressive condition and negative investigations (Figure 2), CT-guided biopsy of the lung lesion was performed, which revealed alveolated lung parenchyma with interstitial thickening due to infiltration of lymphoplasmic cells as well as some eosinophils and a few ill-defined hyaline septate hyphae. After a few days, white yellow colonies grew in Sabouraud dextrose agar. As observed microscopically, it was hyaline mold producing conidia in clusters compatible with *Acremonium* spp. The conidia were elongated and arranged in loose clusters in a crisscross formation at the tip of a long, slender, delicate conidiophore (Figures 3 and 4). Biochemical analysis confirmed the morphological diagnosis of the cultured microorganism to be *Acremonium* spp.

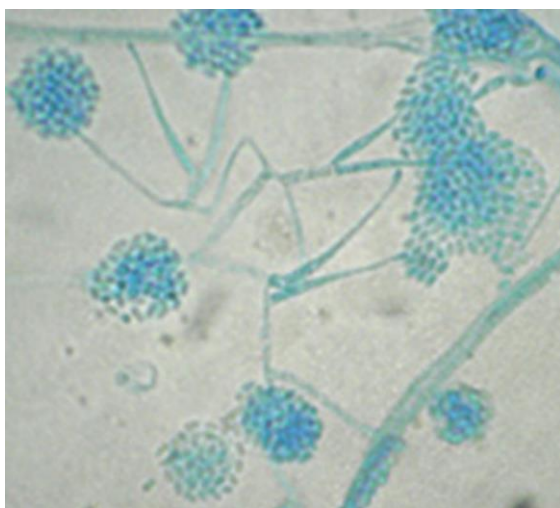
Itraconazole 200 mg twice daily was initiated and within a week, respiratory symptoms ameliorated and after a couple of weeks he was symptom-free and chest-X-ray was completely normal (Figure 5). The patient continued taking itraconazole for a period of 6 months.



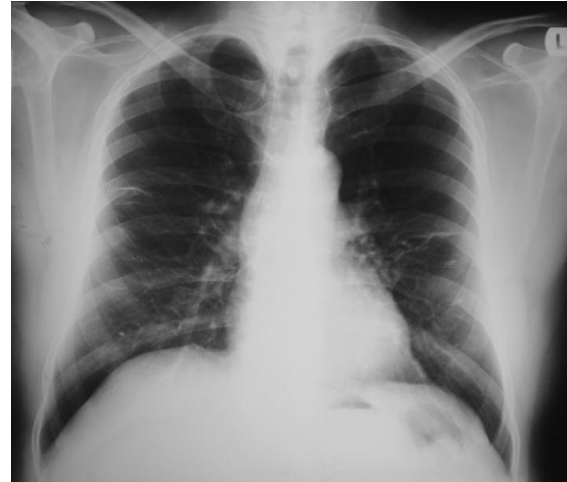**Figure 2.** Chest CT revealed alveolar consolidation and adjacent ground glass opacity in the right lower lobe.



**Figure 3.** Lung biopsy revealed alveolated lung parenchyma with interstitial thickening due to infiltration of lymphoplasmic cells and a few eosinophils.



**Figure 4.** Microscopic view of *Acremonium* hypha and conidia; direct smear of the isolated organism from the culture medium



**Figure 5.** Chest-X-ray 8 weeks after treatment with itraconazole.

## DISCUSSION

This case is extremely rare according to previous reports of all over the world. *Acremonium pneumonia* has been reported in a few case series and single reports (1) occurring in immunocompromised hosts such as leukemic or post-transplantation patients. Although our patient may be considered relatively immunocompromised due to diabetes, we could not find any report of lung infection in patients with minor immunodeficiency. On the other hand, our patient had controlled diabetes according to A1C and FPG analyses, and he had neither microvascular nor macrovascular complications of diabetes. He had no prior episode of infection and physical examinations and laboratory investigations did not demonstrate any other immunodeficiency.

Guarro et al. reviewed all cases of *Acremonium* spp. published in the literature until 1997. Thirty-seven localized and disseminated infections other than well-known superficial infections (skin and ocular) were found. All patients, except for 3 cases whose data regarding possible underlying risk factors were not available, were significantly immunocompromised. Nine patients had documented malignancies and 4 were diagnosed as transplant-related (1).

Five cases of lung infection were reported among them one patient had multiple myeloma with multi-organ

involvement. In a patient with chronic granulocytic leukemia, *Acremonium* was isolated from blood and lungs; two others had concurrent skin infection occurred after trauma and environmental inoculation (1). Only in one patient with underlying chronic granulomatous disease (CGD), an isolated pulmonary infection was noted.

Literature review since 1997 revealed 39 cases of systemic infections in addition to previous reports. All of them were in patients with significant immunodeficiency and compromising conditions. CGD, leukemia, bone marrow transplantation, and prolonged neutropenia were found in patient histories. A vast majority of patients (12 cases) had inoculated infections associated with peritoneal dialysis, implanted devices and indwelling catheters. Thus, real systemic infections appeared to be only 15 cases (5-9). Pulmonary infection due to *Acremonium* spp. has only been reported in 10 cases summarized in Table 1.

In a case of colon adenocarcinoma, *Staphylococcus aureus* and *Acremonium strictum* were isolated from the pleural fluid (10). Herrera et al. assumed that indoor exposure to *Acremonium* spp., as a biological contaminant, increased the occurrence of symptoms of asthma in young children; interestingly, their analysis showed greater association of *Acremonium* than dust mites (11). However, the role of *Acremonium* in hypersensitivity pneumonia has not been demonstrated in the literature (12).

Identification of *Acremonium* and differentiation from other similar fungi including *Fusarium*, *Paecilomyces* and etc. is important for histopathologists. A few reports demonstrated misidentification of the aforementioned isolates in tissue biopsy as *Aspergillus* or *Candida* (13).

Odabasi et al. stated that Beta -D glucan (BG) has the potential to identify invasive fungal infections such as *Acremonium* spp. However, further investigations are required to establish a definite cut off for such rare fungal agents. On the other hand, the effect of treatment on the serum levels of BG remains to be clarified (14).

**Table 1.** All cases of pulmonary infections due to *Acremonium* spp. published in the literature

Year of publication	Underlying disease	Involved sites	Species	Reference number
2005	Chronic granulomatous disease	Lungs	<i>A. strictum</i> *	6
2003	Mantle cell lymphoma	Fungemia, skin and lungs	NA**	7
2003	Acute lymphoblastic leukemia	Fungemia, skin and probably lungs	NA	7
2002	Chronic myelocytic lymphoma	Lungs	<i>A. strictum</i>	8
1998	Post-chemotherapy medullary aplasia	Lungs	<i>A. strictum</i>	9
1998	Myeloma	Lung, nail, heart, kidney	<i>A. strictum</i>	1
1991	Acute myelogenous leukemia	Lungs, skin	<i>Acremonium</i> spp.	1
1943	Pneumothorax	Lungs	<i>Acremonium</i> spp.	1
1984	Chronic granulomatous disease	Lungs	<i>A. strictum</i>	1
1993	Multiple trauma	Skin, Lungs	<i>A. strictum</i>	1

\* *Acremonium strictum*, \*\* Not available

Anecdotal reports recommend that treatment of invasive *Acremonium* infections requires a combination of medical treatment with amphotericin B and surgical intervention (4).

A study by Guarro et al. revealed the *Acremonium* strains had little susceptibility to antifungals such as ketoconazole, amphotericin B, 5-fluorocytosine, itraconazole, miconazole, and fluconazole (1). Fluconazole and 5-fluorocytosine were completely ineffective; and amphotericin B was the best choice. A study by Saldarreaga et al. revealed a similar resistance profile for azoles; although voriconazole was not included. They recommended susceptibility testing for *Acremonium* spp. due to high-rate of resistance to azoles (15).

Recently, several cases of successful treatment with voriconazole have been published and it seems that voriconazole, at least according to case series, is going to be the choice of treatment for *Acremonium*; although, this topic remains to be studied with appropriately designed clinical trials and more cases (7). Interestingly, our patient was treated efficiently with itraconazole without any complication.

## CONCLUSION

*Acremonium* fungal infection may emerge in immunocompromised hosts particularly after chemotherapy, in post-transplantation period and in patients with primary immunodeficiency e.g. CGD. Physicians should be aware of rare fungal pathogens in patients with non-resolving pneumonia.

To our knowledge, this case is the first pulmonary infection caused by *Acremonium* in a patient without significant immunodeficiency except for well-controlled diabetes. Interestingly, in contrast to previous reports, our case was successfully treated with itraconazole and his follow-up revealed complete remission without respiratory or systemic complications.

## REFERENCES

- Guarro J, Gams W, Pujol I, Gené J. *Acremonium* species: new emerging fungal opportunists--in vitro antifungal susceptibilities and review. *Clin Infect Dis* 1997; 25 (5): 1222- 9.
- Kwon-Chung KJ, Bennett JE. Mycetoma. In: Medical Mycology. Philadelphia: Lea & Febiger; 1992:560-93.
- Hay RJ. Dermatophytosis and Other Superficial Mycoses. In: Mandell GL, Bennett JE and Dolin R (Editors). Principles and Practice of Infectious Diseases. 8th Edition. Philadelphia: Churchill and Livingstone Elsevier; 2010: 3345-55.
- Fincher RM, Fisher JF, Lovell RD, Newman CL, Espinel-Ingroff A, Shadomy HJ. Infection due to the fungus *Acremonium* (cephalosporium). *Medicine (Baltimore)* 1991; 70 (6): 398- 409.
- Khan Z, Al-Obaid K, Ahmad S, Ghani AA, Joseph L, Chandy R. *Acremonium kiliense*: reappraisal of its clinical significance. *J Clin Microbiol* 2011; 49 (6): 2342- 7.
- Pastorino AC, Menezes UP, Marques HH, Vallada MG, Cappellozi VL, Carnide EM, et al. *Acremonium kiliense* infection in a child with chronic granulomatous disease. *Braz J Infect Dis* 2005; 9 (6): 529- 34.
- Mattei D, Mordini N, Lo Nigro C, Gallamini A, Osenda M, Pugno F, et al. Successful treatment of *Acremonium* fungemia with voriconazole. *Mycoses* 2003; 46 (11-12): 511- 4.
- Herbrecht R, Letscher-Bru V, Fohrer C, Campos F, Natarajan-Ame S, Zamfir A, et al. *Acremonium strictum* pulmonary infection in a leukemic patient successfully treated with posaconazole after failure of amphotericin B. *Eur J Clin Microbiol Infect Dis* 2002; 21 (11): 814- 7.
- Breton P, Germaud P, Morin O, Audouin AF, Milpied N, Harousseau JL. Rare pulmonary mycoses in patients with hematologic diseases. *Rev Pneumol Clin* 1998; 54 (5): 253- 7.
- Nedret Koç A, Mutlu Sarigüzel F, Artış T. Isolation of *Acremonium strictum* from pleural fluid of a patient with colon adenocarcinoma. *Mycoses* 2009; 52 (2): 190- 2.
- Herrera AB, Rodríguez LA, Niederbacher J. Biological pollution and its relationship with respiratory symptoms indicative of asthma, Bucaramanga, Colombia. *Biomedica* 2011; 31 (3): 357- 71.
- Unoura K, Miyazaki Y, Sumi Y, Tamaoka M, Sugita T, Inase N. Identification of fungal DNA in BALF from patients with home-related hypersensitivity pneumonitis. *Respir Med* 2011; 105 (11): 1696- 703.
- Liu K, Howell DN, Perfect JR, Schell WA. Morphologic criteria for the preliminary identification of *Fusarium*, *Paecilomyces*, and *Acremonium* species by histopathology. *Am J Clin Pathol* 1998; 109 (1): 45- 54.
- Odabasi Z, Mattiuzzi G, Estey E, Kantarjian H, Saeki F, Ridge RJ, et al. Beta-D-glucan as a diagnostic adjunct for invasive fungal infections: validation, cutoff development, and performance in patients with acute myelogenous leukemia and myelodysplastic syndrome. *Clin Infect Dis* 2004; 39 (2): 199- 205.
- Saldarreaga A, Garcia Martos P, Ruiz Aragón J, García Agudo L, Montes de Oca M, Puerto JL, et al. Antifungal susceptibility of *Acremonium* species using E-test and Sensititre. *Rev Esp Quimioter* 2004; 17 (1): 44- 7.