

*Tanaffos* (2003) 2(5), 63-69

©2003 NRITLD, National Research Institute of Tuberculosis and Lung Disease, Iran

## Congenital Lobar Emphysema; a Case Report Presenting with Respiratory Distress

Afshin Ghaleh Golab Behbahan <sup>1</sup>, Hassan Heidarneshad <sup>2</sup>, Shahryar Hashemzadeh <sup>3</sup>, Shahla Talghini <sup>4</sup>

<sup>1</sup>Pediatric Unit, Tabriz Children's Hospital, <sup>2</sup>Respiratory Medicine Unit, Tuberculosis and Respiratory Research Center, <sup>3</sup>Thoracic Surgery Unit, <sup>4</sup>Department of Pathology, Imam Khomeini Hospital, Tabriz University of Medical Sciences and Health Services, TABRIZ- IRAN

### ABSTRACT

*Congenital lobar emphysema (CLE) is a cause of respiratory distress in newborns and infants. In this study we presented a complicated case of CLE in a 35-day-old infant who was treated successfully with surgical intervention. We reviewed several articles and texts to offer a complete discussion about clinical and paraclinical aspects of this entity. (Tanaffos 2003; 2(5): 63-69)*

### INTRODUCTION

Congenital lobar emphysema (CLE) is a condition characterized by severe progressive over-inflation, usually of one lobe with compression of remaining of the lung and mediastinal structures (1). It is more common in Caucasian male newborns and presents classically during the first week of life, and requires surgical resection of the affected lobe/s for cure(1-3).

### CLINICAL SUMMARY

A 35-day-old female infant referred to Tabriz children's hospital with rapid breathing and bluish discoloration of skin and lips from one day prior to admission. The patient's mother said that her daughter had no previous health problem up to one day before admission when she had a choking attack during breast feeding in supine position. Then cough and difficult breathing began and continued. No significant perinatal event mentioned. No family

history of pulmonary diseases were recorded. In physical examination, the patient was febrile (T= 38°C, axillary) and tachypneic (RR= 70 BPM) with central cyanosis, subcostal and intercostals retractions, nasal flaring, and decreased breathing sounds in right hemithorax. No finding was noted in other parts. Clinical work-up including chest x-ray, arterial blood gas, cell count, and blood culture carried out (table 1).

Table 1. Laboratory Study

CBC	ABG	Blood Culture:
Hgb= 11.3 g/dl	pH= 7.36	No Bacterial growth
Hct= 34%	PCo <sub>2</sub> = 28	
WBC=8700/μl	PaO <sub>2</sub> = 52	
<u>Differential:</u>	O <sub>2</sub> Sat= 84%	
PMN= 58%	Hco <sub>3</sub> =11.8	
Lymph= 40%		
Monocyte= 2%		
ESR: (1st Hr)= 32		

Correspondence to: Heidarneshad H

Tel.: +98-21-2803550

E-mail address: hheidarneshad@yahoo.com

In chest x-ray, there was hyperlucency in middle and lower zone of right hemithorax with relative haziness of all left lung as well as upper zone of right lung with decreased volume of these areas, which caused mediastinal shift to the left (Fig-1).

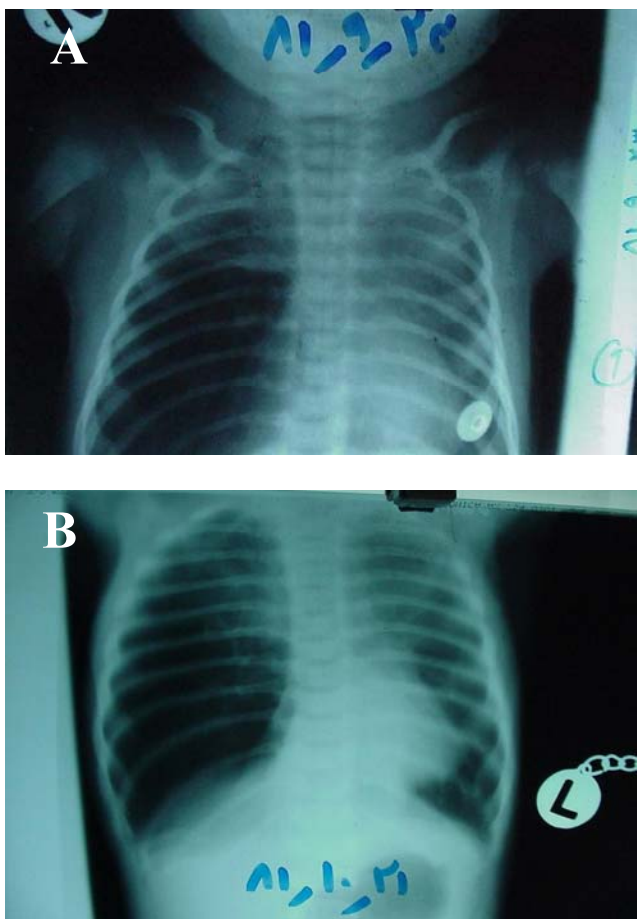


Fig 1 (A,B). Chest x-rays of patient

The patient was treated with antibiotics and other supportive cares with initial impression of aspiration pneumonia. Rigid bronchoscopy was done on the third day of admission that showed a copious amount of thick suppurative discharge in both right and left main bronchi, which was suctioned and cleared.

No foreign body or airway abnormality including bronchomalacia was noted. After 3 weeks of medical treatment, the infant improved partially, fever and cyanosis disappeared and respiratory distress decreased, but control x-rays showed no change in

radiographic appearance, and oxygen dependency developed. CT-scan of thorax was performed which was in favor of lobar emphysema with extensive hyperinflation in right upper and middle lobes associated with mediastinal shift to the left and collapse of right lower lobe (Fig-2).

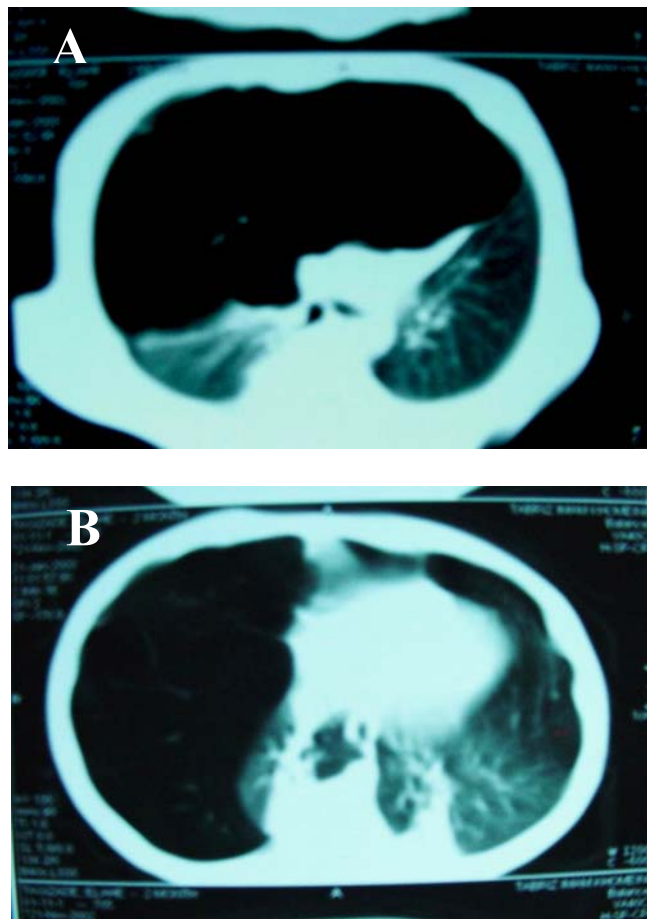
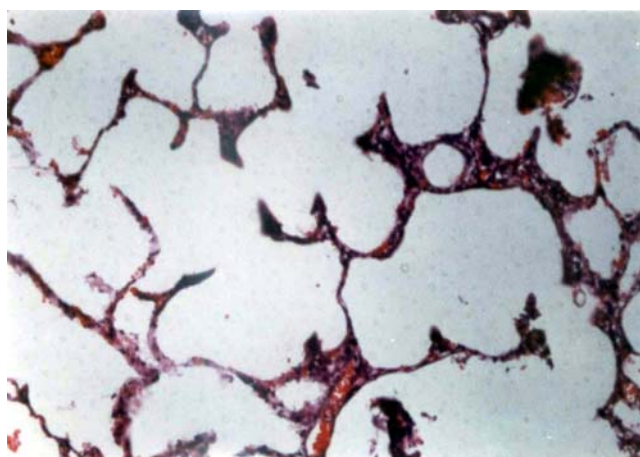


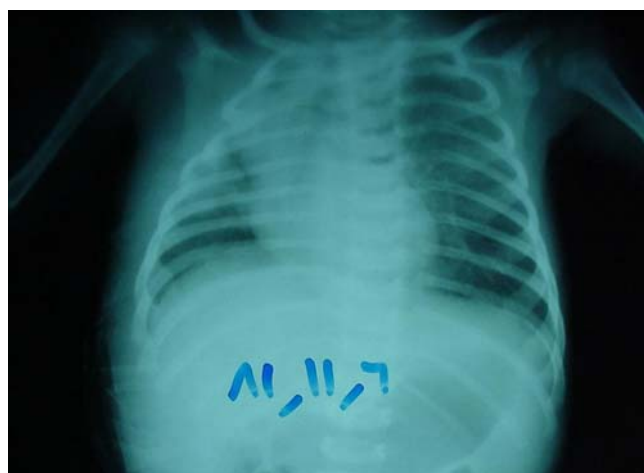Fig 2 (A,B). CT-Scans of patient

A fiberoptic bronchoscopy with thin 3C20 Olympus was done immediately, which revealed tracheal displacement to the left with compression effect to right bronchi without sign of bronchomalacia. The patient transferred to the thoracic surgery ward where emergency thoracotomy and resection of upper and middle lobes of right lung were performed. Gross appearance of excised lobes was in favor of lobar emphysema with non-collapsing hyperinflation which was proved by histopathological examination (Fig-3).



**Fig 3.** Histopathological examination of patient

Twenty-four hours after surgery, the patient completely recovered clinico-radiographically (Fig-4) and discharged from hospital a few days later without any respiratory difficulty.



**Fig 4.** Chest x-ray of patient after surgery

## DISCUSSION

Causative factors of CLE could be found only in half of the cases which include: 1) partial bronchial obstruction, due to cartilage abnormalities such as completely absent, hypoplastic, flaccid, or immature cartilage; however, bronchomalacia is the most common abnormality (1); exuberant mucosal fold; extrinsic vascular or lymph node compression of bronchi, e.g. congenital aortic pulmonary artery;

bronchial distortion from an anterior mediastinal lung hernia; and retained secretions. 2) Intrinsic alveolar disease, including; tears in the alveolar walls or enlarged pores of Kohn; abnormal collagen deposition in the alveolar walls and the supporting stroma (1,2,4,5). There are some case reports showing that congenital cytomegalovirus infection may play some role in the development of CLE (6).

The manifestation of CLE is usually a progressive severe form of respiratory distress. Frequently, upper respiratory tract infection may be found at the presenting time in the form of wheezing, cough, or recurrent chest infection in older children (1,5). In the majority of patients with CLE, symptoms develop in infancy, half of the patients are symptomatic within the first days of life, and most of the remaining patients exhibit symptoms by the age of 4-6 months old. Intermittent bouts of dyspnea, tachypnea, wheezing, cough, and cyanosis are precipitated by feeding, crying, or excitement may be seen (1,4,7). The respiratory symptoms are progressively worsened, eventually becoming persistent and severe.

Acute development of severe respiratory distress necessitating emergency surgical intervention occurs in about 12% of patients, often in association with an acute upper respiratory tract infection (1). Physical examination in severe cases shows distension of the chest wall on the side of the affected lobe with widening of intercostal spaces, chest wall retractions, hyperresonance on percussion, and diminished breathing sounds on auscultation over the affected lung. The apical cardiac pulse and the trachea may be shifted away from the hyperinflated side. Abnormal prominence of the liver or the spleen can result from flattening of the diaphragm on the affected side (1,4,5,7,8). Some associated congenital abnormalities may be found such as congenital heart disease, gastrointestinal, renal, and sacral anomalies (5).

The chest x-ray in CLE shows enlarged and markedly hyperlucent lobe, but lung markings are visible throughout the lobe. This character distinguishes CLE from cysts, diaphragmatic hernia or pneumothorax. The left upper lobe is most frequently involved. Another findings in serial plain chest radiographs include progressive atelectasis of the ipsilateral normal lung, mediastinal shift away from the involved side, and compression of the contralateral lung (1,2,4,7). In neonates, chest x-ray often initially reveals an opaque, fluid-filled lobe that gradually becomes radiolucent as the fluid is absorbed. In fluoroscopy, the hyperinflated lobe remains constant in area, regardless of the phase of respiration and diaphragm on the affected side moves poorly. The mediastinum shifts toward the emphysematous side during inspiration and away from it during exhalation (1). Bronchoscopy should be performed in older children especially who become symptomatic after 6 months of age (4), to exclude a potentially remediable bronchial obstruction such as inspissated mucus or aspirated foreign body, which are more likely causes emphysema in comparison with CLE in these patients. In infants with suspected CLE, however, rigid bronchoscopy with the ventilating bronchoscope can lead to rapid deterioration because the positive-pressure ventilation causes increasing hyperinflation of the affected lobe (9). Fiberoptic bronchoscopy is a safer alternative but should be attempted only in patients who are clinically stable. Bronchography can also result in rapid deterioration of the patient's condition, but it is not often helpful; although it may show that bronchial tree of the affected lobe tends not to fill, even if no bronchial obstruction is found at resection. When the bronchi do fill, they show widely separated segments (1). The barium swallow is useful for ruling out vascular ring or mediastinal mass. Thoracic CT-Scan with contrast can show a small subcarinal or perihilar

bronchogenic cyst that may not be visible on the chest x-ray. The CT scan also demonstrates the typical widely separated vascular pattern of CLE and sometimes identifies an area of localized bronchial narrowing (1,10). Magnetic resonance imaging can be used to detect abnormal mediastinal structures or anomalous blood vessels. Ventilation-perfusion scanning of the lung is not usually necessary in the diagnosis of CLE; however, it can be helpful in distinguishing CLE from compensatory emphysema. In CLE, matched defects in V/Q are found whereas in compensatory emphysema, V/Q of the emphysematous lobe is normal. Prenatal diagnosis of CLE may be possible by fetal sonography which can show echogenic or cystic lung (11-14). CLE must be differentiated from compensatory emphysema, reversible obstructive emphysema, large cystic lesions, diaphragmatic hernia, pneumothorax, and unilateral hyperlucent lung (Swyer-James) syndrome. In which obliterative bronchiolitis and markedly decreased pulmonary blood flow to one lung follow a severe episode of pneumonia, shares some radiographic characteristics with CLE, however in this syndrome the volume of hyperlucent lung is slightly decreased and there is no compression of normal lung tissue and the mediastinum may be shifted toward the more abnormal lung (15). The hyperlucency of the lung appears to be secondary to the decrease in perfusion rather than emphysema (1,4). A syndrome of acquired lobar emphysema in infants with bronchopulmonary dysplasia (chronic lung disease) was described by Cooney et al. (16), two subsets of patients were identified: those with normal lung perfusion scan, who were successfully weaned from the ventilator and finally showed complete resolution of the emphysema, and those with markedly decreased perfusion of the emphysematous lobe, who required lobectomy.

For infants with typical CLE and progressive respiratory distress, immediate surgical intervention

is indicated (17). Without surgery, the mortality rate among these patients is 50%, and 75% of the survivors have persistent respiratory distress; however, older children with mild or asymptomatic form of disease have been managed conservatively without serious sequel. (1,18,19). In one study, comparing long-term evaluation of 6 surgically and 5 conservatively treated children with CLE, no significant difference in their pulmonary function test and lung growth observed. Of course conservatively treated patients had mild or asymptomatic disease, but those who were resected had severe respiratory distress preoperatively (20).

Early age, concomitant congenital heart disease which may be found at least in 10% of patients with CLE, or severe respiratory symptoms should not contraindicate operation (4). The surgical treatment of choice is lobectomy. When two lobes are involved, staged lobectomies with removal of the more hyperinflated lobe have first been successful. During the induction of anesthesia, vigorous positive pressure may inflate the emphysematous lobe and produce an extension of respiratory distress. To prevent this event; "high frequency jet ventilation" and "continuous caudal epidural analgesia for thoracotomy" have been used for resection of CLE (21,22).

In induction of anesthesia in our patient, we used selective left mainstem bronchial intubation as well as ventilation, and no change in patient's arterial blood gas measures was occurred.

The mortality rate among surgically treated patients is less than 5%. Most of these deaths have been related to concomitant heart disease or hypoxic brain damage. In some patients, diffuse fatal emphysema develops postoperatively, and some patients have recurrent wheezing (1,4). In long-term follow up of pulmonary function after lobectomy for CLE, some investigators have found evidence of compensatory lung growth. Other studies of pulmonary functions,

however, reveal persistent defects including increased functional residual volume, total lung capacity, and decreased mid-expiratory flow rates. Despite the abnormalities on pulmonary function tests, most surgically treated patients will be asymptomatic and will have normal growth and development (1,4).

## REFERENCES

1. Lierl M. Congenital abnormalities in: Pediatric respiratory disease: Diagnosis and treatment, Hilman B.C. 1<sup>st</sup> Ed. W.B. Saunders Company, Philadelphia, 1993; 468-72.
2. Stigers KB, Woodring JH, Kanga JF. The clinical and imaging spectrum of findings in patients with congenital lobar emphysema. *Pediatr Pulmonol* 1992; 14(3): 160-70.
3. Thakral CL, Maji DC, Sajwani MJ. Congenital lobar emphysema: experience with 21 cases. *Pediatr Surg Int* 2001; 17(2-3): 88-91.
4. Krummel TM. Congenital malformation of the lower respiratory tract in: Kendig's disorders of the respiratory tract in children, Chernick V., Boat T.F, 6<sup>th</sup> Ed. W.B. Saunders company, Philadelphia, 1998; 310-11.
5. Lincoln JC, Stark J, Subramanian S, Aberdeen E, Bonham-Carter RE, Berry CL, et al. Congenital lobar emphysema. *Ann Surg* 1971; 173(1): 55-62.
6. Carrol ED, Campbell ME, Shaw BN, Pilling DW. Congenital lobar emphysema in congenital cytomegalovirus infection. *Pediatr Radiol* 1996; 26(12): 900-2.
7. Man DW, Hamdy MH, Hendry GM, Bisset WH, Forfar JO. Congenital lobar emphysema: problems in diagnosis and management. *Arch Dis Child* 1983; 58(9): 709-12.
8. Karnak I, Sencak ME, Ciftci AO, Buyukpamukcu N. Congenital lobar emphysema: diagnostic and therapeutic considerations. *J Pediatr Surg* 1999; 34(9): 1347-51.
9. Doull IJ, Connett GJ, Warner JO. Bronchoscopic appearance of congenital lobar emphysema. *Pediatr Pulmonol* 1996; 21(3): 195-7.

10. Rusakow LS, Khare S. Radiographically occult congenital lobar emphysema presenting as unexplained neonatal tachypnea. *Pediatr Pulmonol* 2001; 32(3): 246-9.
11. Quinton AE, Smoleniec JS. Congenital lobar emphysema the disappearing chest mass: antenatal ultrasound appearance. *Ultrasound Obstet Gynecol* 2001; 17(2): 169-71.
12. Babu R, Kyle P, Spicer RD. Prenatal sonographic features of congenital lobar emphysema. *Fetal Diagn Ther* 2001; 16(4): 200-2.
13. Olutoye OO, Coleman BG, Hubbard AM, Adzick NS. Prenatal diagnosis and management of congenital lobar emphysema. *J Pediatr Surg* 2000; 35(5): 792-5.
14. Wansaicheong GK, Ong CL. Congenital lobar emphysema: antenatal diagnosis and follow up. *Australas Radiol* 1999; 43(2): 243-5.
15. Orenstein DM. Emphysema and overinflation, in: Nelson Textbook of Pediatrics, Behrman RE, Kliegman RM, Jenson HB, 16<sup>th</sup> ed. WB. Saunders, Philadelphia, 2000; 1302-3.
16. Cooney DR, Menke JA, Allen JE. Acquired lobar emphysema: a complication of respiratory distress in premature infants. *J Pediatr Surg* 1977; 12(6): 897-904.
17. Dogan R, Demircin M, Sarigul A, Pasaoglu I, Gocmen A, Bozer AY. Surgical management of congenital lobar emphysema. *Turk J Pediatr* 1997; 39(1): 35-44.
18. Gupta R, Singhal SK, Rattan KN, Chhabra B. Management of congenital lobar emphysema with endobronchial intubation and controlled ventilation. *Anesth Analg* 1998; 86(1): 71-3.
19. Philipos EZ, Libsekal K. Flexible bronchoscopy in the management of congenital lobar emphysema in the neonate. *Can Respir J* 1998; 5(3): 219-21.
20. Eigen H, Lemen RJ, Waring WW. Congenital lobar emphysema: long-term evaluation of surgically and conservatively treated children. *Am Rev Respir Dis* 1976; 113(6): 823-31.
21. Goto H, Boozalis ST, Benson KT, Arakawa K. High-frequency jet ventilation for resection of congenital lobar emphysema. *Anesth Analg* 1987; 66(7): 684-6.
22. Raghavendran S, Diwan R, Shah T, Vas L. Continuous caudal epidural analgesia for congenital lobar emphysema: a report of three cases. *Anesth Analg* 2001; 93(2): 348-50.