

Tanaffos (2003) 2(7), 69-77

©2003 NRITLD, National Research Institute of Tuberculosis and Lung Disease, Iran

Dilemma in Management of Diabetic Patients with Pulmonary Mucormycosis

Hamid Reza Jabar Darjani¹, Seyed Mehdi Mirsaeidi², Abbas Mir- Afsharieh³, Mohammad Omid Edrissian¹, Shirin Haghighi¹

¹ Department of Pulmonary Medicine, ² Department of Infectious Diseases, ³ Department of Clinical Anatomical Pathology, NRITLD, Shaheed Beheshti University of Medical Sciences and Health Services, TEHRAN- IRAN

ABSTRACT

Mucormycosis is a rare but lethal infection among immunocompromised patients. In this report, we discussed two cases of pulmonary mucormycosis, a 48-year-old man with the history of diabetes mellitus and paroxysmal nocturnal hemoglobinuria and a 60-year-old woman with the background of diabetes mellitus. (Tanaffos 2003; 2(7): 69-77)

Key words: Diabetes mellitus, Mucormycosis, Paroxysmal Nocturnal Hemoglobinuria

INTRODUCTION

Mucormycosis or phycomycosis (zygomycosis) is a serious fungal infection caused by *Mucor Spp.* It usually affects immunocompromised patients, including diabetic Patients with poorly controlled blood glucose and ketoacidosis. Despite the fact that mucormycosis is a relatively rare infection, it has a lethal nature, and the majority of cases are diagnosed in advanced stages of the disease.

Although the most common type of this disease is the rhinocerebral type, the pulmonary type has showed an increasing incidence during the recent years. (1, 2)

In this report, we present two cases of pulmonary mucormycosis who were referred to our hospital during the years 1999- 2002.

PRESENTATION OF THE FIRST CASE

A 48-year-old man was admitted to the intensive care unit of Massih Daneshvari hospital in March 2001 because of the massive hemoptysis and productive cough that had begun 2 days before the admission. The patient had had the history of fever, chills, night sweating, purulent sputum, and cough 2 months before referring to this hospital.

The patient had suffered from paroxysmal nocturnal hemoglobinuria (PNH) since 14 years before and diabetes mellitus since 3 years before and he had received prednisolone and cyclosporine for 2

Correspondence to: Edrissian MO

Tel.: +98-912-1483975

E-mail address: edrissian@hbi.dmr.or.ir

years. From the time of diagnosis of diabetes mellitus, he had used glibenclamide irregularly for controlling his diabetes. At the time of admission, patient was alert and pale, his blood pressure was 130/ 90 mmHg, pulse rate was 84, and respiratory rate was 28. His temperature showed a low grade fever, 38.4° C. On chest examination, lung sounds were diminished at the base of right lung. The other physical examinations were normal. His chest X- ray

(Figure1) showed consolidations in the middle and lower lobes of the right lung, and lung CT- scan (Figures 2 and 3) confirmed these consolidations in the mentioned areas.

Laboratory findings showed a normochrome normocytic anemia, increased blood glucose, urea, creatinine, and sodium levels. (Table 1).

Table 1. Laboratory tests of the first case

Laboratory values on admission		Laboratory values 18 days after admission	
<u>Hematological variables:</u>	Value	<u>Hematological variables:</u>	Value
Red cell count (per mm ³)	4,260,000	Red cell count (per mm ³)	3,370,000
Hematocrit (%)	42.4	Hematocrit (%)	28.2
Hemoglobin (g/dl)	13.4	Hemoglobin (g/dl)	8.5
Mean corpuscular volume (µm ³)	99.5	Mean corpuscular volume (µm ³)	83.7
White-cell count (per mm ³)	8,400	White-cell count (per mm ³)	42000
<u>Differential count (%)</u>		<u>Differential count (%)</u>	
Neutrophils	74	Neutrophils	66.2
Lymphocytes	23	Lymphocytes	25.8
Monocytes	2	Platelet count (per mm ³)	195,000
Eosinophils	1	Prothrombin time (sec)	13
Platelet count (per mm ³)	193000	Partial-thromboplastin time (sec)	34
Prothrombin time (sec) (activity 96%)	12.8	<u>Blood Chemical Variables:</u>	
Partial-thromboplastin time (sec)	36	Fasting blood sugar (mg/dl)	109
<u>Blood Chemical Variables:</u>		Blood sugar (mg/dl)	380
Fasting blood sugar (mg/dl)	330	Urea (mg/dl)	88
Urea (mg/dl)	40	Creatinine (mg/dl)	1.7
Creatinine (mg/dl)	1.1	Sodium (meq/dl)	147
Sodium (mEq/dl)	145	Potassium (meq/dl)	3.4
Potassium (mEq/dl)	4.7	Uric acid (mg/dl)	6.6
Lactate dehydrogenase (IU/l)	945	Lactate dehydrogenase (IU/l)	725
Aspartate aminotransferase (IU/l)	17	Aspartate aminotransferase (IU/l)	78
Alanine aminotransferase(IU/l)	28	Alanine aminotransferase(IU/l)	94
Alkaline phosphatase (IU/l)	452	Alkaline phosphatase (IU/l)	1307
<u>Urine analysis:</u>		<u>Urine analysis:</u>	
Sugar	+++	Sugar	++
White blood cell	1-2	White blood cell	1-2
Red blood cell	0-1	Red blood cell	2-3
Hemoglobin	-	Hemoglobin	+

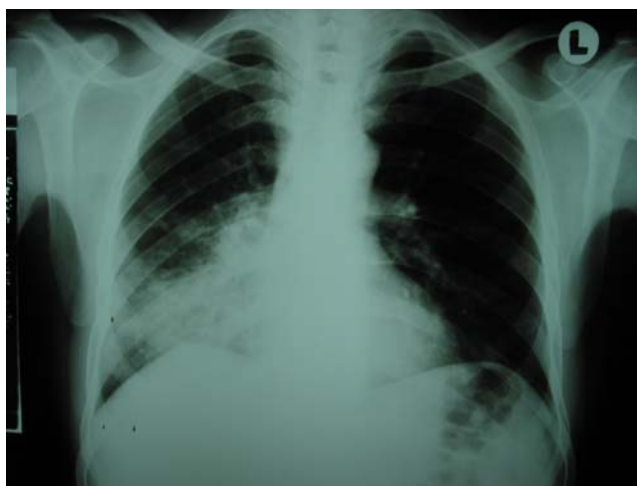

Figure 1. The first case; right paracardiac infiltration (NRITLD, Massih Daneshvari Hospital, Shaheed Beheshti University of Medical Sciences and Health Services, TEHRAN-IRAN)

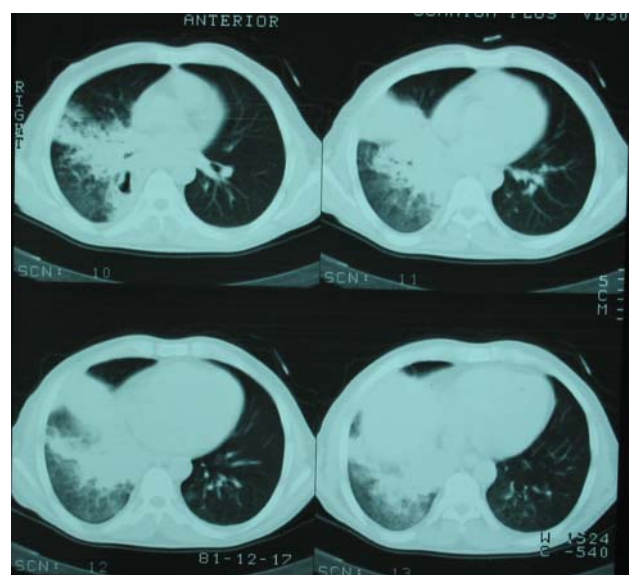


Figure 2. The first case; middle and lower lobes infiltrations (NRITLD, Massih Daneshvari Hospital, Shaheed Beheshti University of Medical Sciences and Health Services, TEHRAN-IRAN)

Bronchoscopic examination of the patient showed a relative occlusion of bronchus intermedius and right middle lobe bronchus due to mucosal edema and infarction along with necrosis in mucosal surface. The result of biopsy and bronchoalveolar

lavage revealed fungal hyphae consistent with mucor.

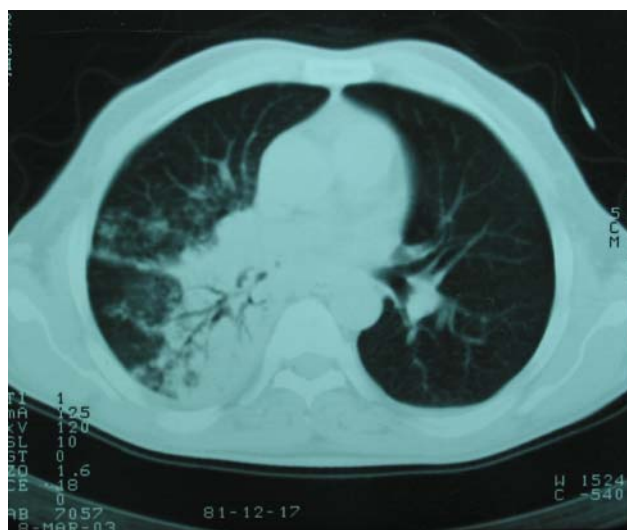

Figure 3. The first case; note the middle and lower lobes involvement in the right lung (NRITLD, Massih Daneshvari Hospital, Shaheed Beheshti University of Medical Sciences and Health Services, TEHRAN-IRAN)

Amphotericin- B, 90 mg daily, had begun for the patient according to the diagnosis of pulmonary mucor. NPH insulin was also prescribed for controlling the blood glucose.

The patient was considered as a candidate for surgical treatment of this fungal disease after 2 weeks, because no improvement was observed despite medical therapy with amphotericin- B. Lower and middle lobes of right lung was surgically removed (bilobectomy of right lung). Pathological examination of removed parts confirmed the diagnosis of mucormycosis by showing coagulative necrosis of pulmonary parenchyma with broad- non septate fungal hyphae bearing, 90-degree-angle branching plus intra-alveolar hemorrhage, and non specific fibro- inflammatory changes (Figure 4).

A few days after, the patient complained about weakness and physical examination showed development of hepatosplenomegaly in the patient. There was also an increase in the level of liver enzymes, especially alkaline phosphatase (Table 1).

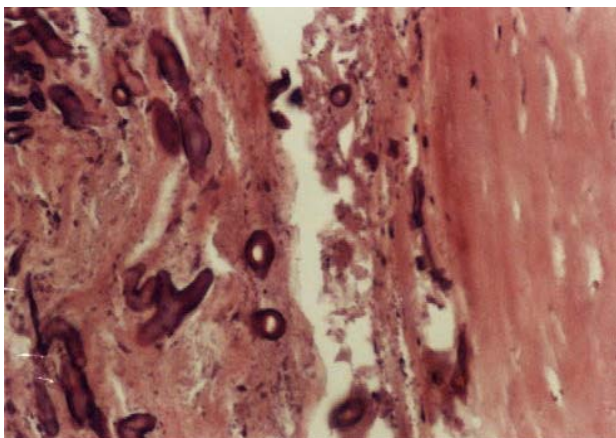


Figure 4. The first case; broad branching non-septate fungal hyphae in necrotic tissue background (NRITLD, Massih Daneshvari Hospital, Shaheed Beheshti University of Medical Sciences and Health Services, TEHRAN-IRAN)

Liver sonography showed a portal hypertension in the patient. Cholestasis and triaditis were also shown in the patient by liver biopsy. These changes took the possibility of disseminated mucormycosis into consideration in the patient. He also complained about severe pain at the site of surgery and became feverish because of developing a broncho- plural fistula in the right lung.

The culture result of chest tube secretions showed *Pseudomonas aeruginosa* infection, and immediately ceftazidime and clindamycine were begun for the patient. In spite of intensive antibiotic therapy, sepsis appeared in the patient. He suffered from cardiac arrest after a sudden massive hemoptysis. CPR was performed for him, but it was not effective; therefore, he expired a week after the operation.

PRESENTATION OF THE SECOND CASE

A 60-year-old woman was admitted to the pulmonary ward of Massih Daneshvari hospital in April 1999 because of 2-month history of dry cough, fever, chills and chest wall pain at the anterior and antero- lateral part of right hemi-thorax.

The patient was a housewife and also was working as a traditional baker at home. She had received various types of antibiotics previously because of her cough. However, no improvement in symptoms was observed. The patient had had diabetes mellitus for 15 years, and at the time of admission, she was using glibenclamide, two tablets daily, as the treatment of her diabetes. In the physical exam, the patient was alert and cooperative. Her pulse rate was 86 and regular, respiratory rate was 18, and temperature was 37.4° C. Except for an umbilical hernia, other physical examination revealed no abnormality with the exception of a moderate hypertension (blood pressure was 160/ 90 mmHg). Laboratory findings were also normal, except for FBS, which was 321 mg/ dl (Table 2).

Sputum smear was negative for tuberculosis. The chest X- ray showed a consolidation in the right middle lobe (Figure 5). Seven days after admission to the hospital, the patient was considered as candidate for bronchoscopic examination for further investigation of chest X- ray abnormality. Trans-bronchial examination revealed a vegetative necrotic lesion in the upper lobe of right lung, and during the biopsy from the lesion, the patient suddenly had generalized seizure and immediately was transferred to the ICU.

The patient was intubated, and convulsion was controlled by intravenous phenytoin; however, the patient entered the coma status consequently. Neurological examination in this state showed normal vital signs, spontaneous respiration with normal pattern, normal reactive pupils, symmetric tendon reflexes (1+), negative plantar reflex, and GCS was 5/ 15. Caloric test revealed no brain stem abnormality. Brain CT scan showed wide hypodensity in right fronto- parietal and both parieto- occipital areas, (Figure 6). After using contrast, gyral enhancement and a ring enhancement in caudate area were seen in CT scan. These signs were consistent with cerebrovascular accident.

Table 2. Laboratory tests of the second case

Laboratory values on admission		Laboratory values 10 days after admission	
<u>Hematological variables:</u>	Value	<u>Hematological variables:</u>	Value
Hematocrit (%)	43	Hematocrit (%)	43.1
Hemoglobin (g/dl)	14.5	Hemoglobin (g/dl)	13.4
White-cell count (per mm ³)	7,600	White-cell count (per mm ³)	18,900
<u>Differential count (%)</u>		<u>Differential count (%)</u>	
Neutrophils	60	Neutrophils	95
Lymphocytes	34	Lymphocytes	4
Monocytes	2	Monocytes	1
Eosinophils	4	Poikilocytosis (Burr cells) & Target cells with mild macrocytosis	
Platelet count (per mm ³)	285000	Platelet count (per mm ³)	268,000
Prothrombin time (sec) (activity 72%)	14.5	Prothrombin time (sec) (activity 60%)	15.8
Partial-thromboplastin time (sec)	47	Partial-thromboplastin time (sec)	51
<u>Blood Chemical Variables:</u>		<u>Blood Chemical Variables:</u>	
Fasting blood sugar (mg/dl)	321	Fasting blood sugar (mg/dl)	249
Urea (mg/dl)	28	Urea (mg/dl)	42
Creatinine (mg/dl)	0.8	Creatinine (mg/dl)	0.9
Calcium (mg/dl)	9	Sodium (meq/dl)	139
Sodium (meq/dl)	140	Potassium (meq/dl)	4
Potassium (meq/dl)	4.1		

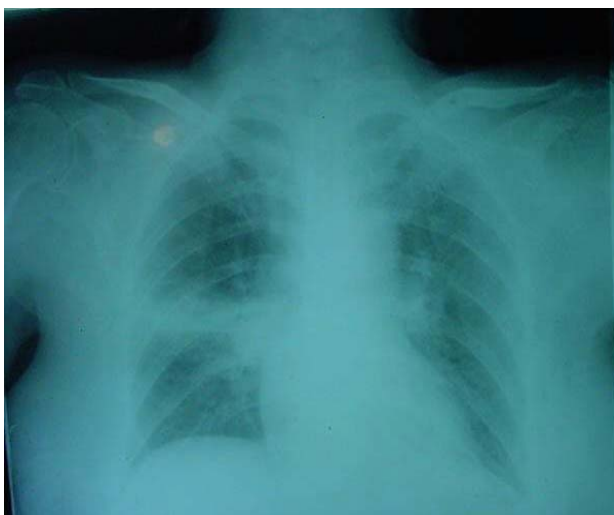


Figure 5. The second case; Hilar prominency and right upper lobe infiltration (NRITLD, Massih Daneshvari Hospital, Shaheed Beheshti University of Medical Sciences and Health Services, TEHRAN-IRAN)

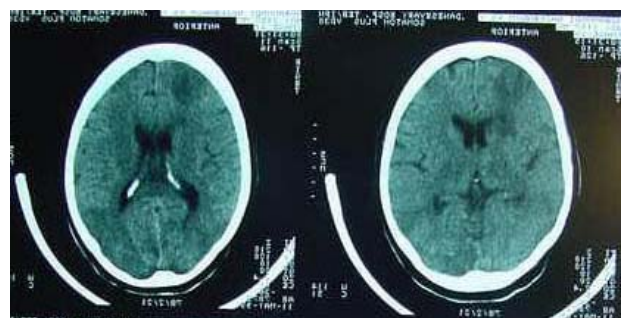


Figure 6. The second case; note the hypodense areas in the right fronto-parietal and both sided parieto-occipital lobes. (NRITLD, Massih Daneshvari Hospital, Shaheed Beheshti University of Medical Sciences and Health Services, TEHRAN-IRAN)

The microscopic examination of pulmonary lesion at this time showed fungal organisms composed of broad branching, non-septate hyphae in a background

of necrotic tissue, consistent with mucormycosis (Figure 7).

According to the diagnosis of mucormycosis, amphotericin-B with a dose of 50 mg daily was prescribed for the patient. The patient also received cimetidine, sucralfate, phenytoin, dexamethasone, insulin, and heparin in the ICU. The general condition of patient did not change until 10 days later, when the patient had cardiac arrest after a massive hematemesis due to the severe gastrointestinal bleeding, probably because of a stress ulcer. CPR was done, but it was not effective; thus, the patient expired.

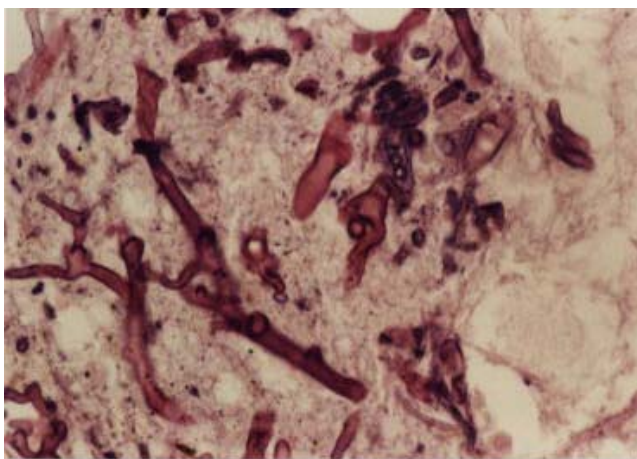


Figure 7. The second case; broad non-septate fungal hyphae with right angle branching (NRITLD, Massih Daneshvari Hospital, Shaheed Beheshti University of Medical Sciences and Health Services, TEHRAN-IRAN)

DISCUSSION

Diabetes mellitus is one of the major predisposing factors for mucormycosis. About 50 percent of rhinocerebral mucormycosis occur in diabetic patients, especially among those who have ketoacidosis; however all types of mucormycosis manifestations can occur in both type I and type II of diabetic patients (1, 3, 4, 5). Neutrophils play a major role in host defense against mucorals, and in diabetics the function of neutrophils is impaired at

different levels. (1, 6, 7) The nature of background disease is also important in the prognosis of mucormycosis. It seems that the survival rate of diabetic patients is better than those having other underlying systemic diseases (8).

Pulmonary mucormycosis has a high mortality rate. Study of 255 cases of mucormycosis showed that the hospital mortality was 65 percent for patients with isolated pulmonary mucormycosis and 96 percent for patients with disseminated disease. Overall mortality rate was 80 percent (1). The conventional treatments for pulmonary mucormycosis are amphotericin-B and its less toxic lipid-based variety, liposomal amphotericin-B, as well as surgical intervention (2, 9). The mortality also varies based on the type of treatment. The mortality rate among the patients who were treated surgically was 11 percent as compared to 68 percent in patients who received medical treatment (1). There is no improvement in many of mucormycosis cases who are treated with amphotericin-B, especially in those with advanced disease and in disseminated cases. (9) In addition, because of the nephrotoxic effects of this drug, it cannot be administered in high doses for a long period, especially in cases that have renal problems because of their underlying diseases. In the recent years, using its liposomal preparation has solved this problem to some extent and can be administered in higher doses in these patients. (9, 10) We have reported two cases of pulmonary mucormycosis with diabetes mellitus. Both patients had type II diabetes mellitus without signs and symptoms of ketoacidosis. It seems that the progression of this disease among diabetics is less acute than that of the other predisposed groups (11). This less fulminant trend was observed more or less in our cases at the time of their admission as well.

One of the cases had a history of paroxysmal nocturnal hemoglobinuria too. Besides the immunocompromised patients and diabetics (12, 13),

there are some reports of mucormycosis in patients with immune deficient disorders like Behcet's disease and systemic lupus erythematosus. However, we could not find any association between this fungal infection with paroxysmal nocturnal hemoglobinuria in the literature. The patient with paroxysmal nocturnal hemoglobinuria had a history of poorly-controlled diabetes mellitus as well and he was not neutropenic at the time of admission. He had also received corticosteroid 2 years before the admission. Since chronic treatment with corticosteroid is one of the important predisposing factors for mucormycosis (14, 15), diabetes along with chronic corticosteroid therapy may be considered as the major risk factors for developing pulmonary mucormycosis in this patient. However, some qualitative disturbances in neutrophils were also reported in paroxysmal nocturnal hemoglobinuria (16). The massive hemoptysis in this patient could be explained by vascular invasion of mucor (17, 18), while progressive liver and spleen involvement after the operation could be explained by the dissemination of mucormycosis in spite of intensive therapy with amphotericin- B. However, it was not proved in our case because of the lacking autopsy evidences in this regard.

Cerebrovascular accident is not an uncommon complication of mucormycosis (13, 19, 20). Invasion of arteriols by fungi hyphae or rupture of fungal microaneurysm leads to cerebral infarct in these patients. In some cases, these cerebrovascular involvement do not have any clinical manifestation before the infarction, and in most of the cases, role of mucor in cerebrovascular infarction is revealed after death. Our second case had a cerebrovascular accident during bronchoscopic biopsy.

There are some reports of stroke during or after an invasive procedure like beginning of chemotherapy for cancer treatment in mucormycosis patients (20,21). It seems that aged patients with

mucormycosis who have a predisposing disease that increases the risk of microvascular injuries are susceptible to stroke during the invasive diagnostic or therapeutic procedures. Because autopsy was not done in this case, relation between the cause of patient's stroke and mucor invasion of cerebral arterioles was not proven.

To conclude, our experience regarding these two cases of pulmonary mucormycosis intensifies the importance of early diagnosis and intensive treatment of these patients.

Considering this infection and performing a careful physical examination would help in early diagnosis and management of this disease, despite of its low prevalence. According to the patient's medical condition, role of early surgical intervention is much more important than that of medical therapy in pulmonary mucormycosis. It is also important to consider the risk of stroke before performing any invasive procedure in these patients, especially in those who have a possible background of microvascular damage according to their predisposing diseases.

REFERENCES

1. Tedder M, Spratt JA, Anstadt MP, Hegde SS, Tedder SD, Lowe JE. Pulmonary mucormycosis: results of medical and surgical therapy. *Ann Thorac Surg* 1994; 57(4): 1044- 50.
2. Sugar, AM. Agents of Mucormycosis and Related Species. In: Mandell, Gerald L, John E, Bennett, and R a Prael Dolin. (Eds) Principles and Practice of Infectious Disease, 5th Ed. (2000) Churchill Livingstone. Philadelphia. pp 2685-2695. Vol 5. Chater 249.
3. Joshi N, Caputo GM, Weitekamp MR, Karchmer AW. Infections in patients with diabetes mellitus. *N Engl J Med* 1999; 341 (25) : 1906- 12.
4. Bhansali A, Sharma A, Kashyap A, Gupta A, Dash RJ. Mucor endophthalmitis. *Acta Ophthalmol Scand* 2001; 79(1): 88- 90.

5. Tsaousis G, Koutsouri A, Gatsiou C, Paniara O, Peppas C, Chalevelakis G. Liver and brain mucormycosis in a diabetic patient type II successfully treated with liposomal amphotericin B. *Scand J Infect Dis* 2000; 32(3): 335-7.
6. Waldorf AR, Ruderman N, Diamond RD. Specific susceptibility to mucormycosis in murine diabetes and bronchoalveolar macrophage defense against *Rhizopus*. *J Clin Invest* 1984; 74(1): 150-60.
7. Waldorf AR, Levitz SM, Diamond RD. In vivo bronchoalveolar macrophage defense against *Rhizopus oryzae* and *Aspergillus fumigatus*. *J Infect Dis* 1984; 150(5): 752-60.
8. Blitzer A, Lawson W, Meyers BR, Biller HF. Patient survival factors in paranasal sinus mucormycosis. *Laryngoscope* 1980; 90(4): 635-48.
9. Ribes JA, Vanover-Sams CL, Baker DJ. Zygomycetes in human disease. *Clin Microbiol Rev* 2000; 13(2): 236-301.
10. Ng AW, Wasan KM, Lopez-Berestein G. Development of liposomal polyene antibiotics: an historical perspective. *J Pharm Pharm Sci* 2003; 6(1): 67-83.
11. Rothstein RD, Simon GL. Subacute pulmonary mucormycosis. *J Med Vet Mycol* 1986; 24(5): 391-4.
12. Santo M, Levy A, Levy MJ, Weinberger A, Mor R, Avidor I, et al. Pneumonectomy in pulmonary mucormycosis complicating Behcet's disease. *Postgrad Med J* 1986; 62(728): 485-6.
13. Liu MF, Chen FF, Hsiue TR, Liu CC. Disseminated zygomycosis simulating cerebrovascular disease and pulmonary alveolar haemorrhage in a patient with systemic lupus erythematosus. *Clin Rheumatol* 2000; 19(4): 311-4.
14. McNulty JS. Rhinocerebral mucormycosis: predisposing factors. *Laryngoscope* 1982; 92(10 Pt 1): 1140-3.
15. Winkler S, Susani S, Willinger B, Apsnre R, Rosenkranz AR, Potzi R, et al. Gastric mucormycosis due to *Rhizopus oryzae* in a renal transplant recipient. *J Clin Microbiol* 1996; 34(10): 2585-7.
16. Gonzalez Moraleja J, Rubio Perez P, Cabello Carro J, Garcia-Casasola G, Alvarez-Sala JL. Recurrent infections, severe neutropenia and neutrophil chemotaxis defect in paroxysmal nocturnal hemoglobinuria. *An Med Interna* 1994; 11(10): 490-2.
17. Harada M, Manabe T, Yamashita K, Okamoto N. Pulmonary mucormycosis with fatal massive hemoptysis. *Acta Pathol Jpn* 1992; 42(1): 49-55.
18. Yagihashi S, Watanabe K, Nagai K, Okudaira M. Pulmonary mucormycosis presenting as massive fatal hemoptysis in a hemodialytic patient with chronic renal failure. *Klin Wochenschr* 1991; 69(5): 224-7.
19. Moja M, Muthuphei MN, van der Westhuizen LR, Gledhill RF. Multiple infarcts in a patient with cerebral phaeohyphomycosis: CT and MRI. *Neuroradiology* 2000; 42(4): 261-6.
20. Zarei M, Morris J, Aachi V, Gregory R, Meanock C, Brito-Babapulle F. Acute isolated cerebral mucormycosis in a patient with high grade non-Hodgkins lymphoma. *Eur J Neurol* 2000; 7(4): 443-7.
21. Mathur SC, Friedman HD, Kende AI, Davis RL, Graziano SL. Cryptic *Mucor* infection leading to massive cerebral infarction at initiation of antileukemic chemotherapy. *Ann Hematol* 1999; 78(5): 241-5.