

Tanaffos (2005) 4 (13), 21- 25

©2005 NRITLD, National Research Institute of Tuberculosis and Lung Disease, Iran

Effects of Clonidine Premedication on Hemodynamic Responses during Fiberoptic Bronchoscopy

Davood Attaran¹, Mohammad Towhidi¹, Amir Hashem Asnaashari¹, Fariba Mansoori¹, Mohammad Khajedalui²

¹ Department of Pulmonary Medicine, ² Department of Epidemiology, Mashad University of Medical Sciences and Health Services, MASHAD-IRAN.

ABSTRACT

Background: Fiberoptic bronchoscopy is occasionally associated with significant hemodynamic complications such as hypertension, tachycardia and arrhythmia. The ability of α_2 adrenoreceptor agonists to inhibit central sympathetic outflow may benefit the patients undergoing bronchoscopy by reducing the incidence and severity of hemodynamic abnormalities.

Materials and Methods: We designed this study to examine whether clonidine given as an oral premedication would attenuate the hemodynamic stress response during fiberoptic bronchoscopy. We performed a prospective, randomized, double blind study on one hundred patients scheduled for bronchoscopy to evaluate the effects of 300 μ g oral clonidine premedication on the hemodynamic alteration and incidence of ECG changes.

Results: During the procedure, patients receiving placebo exhibited a significant increase in mean arterial pressure (97 ± 18 to 120 ± 17 mmHg) and heart rate (90 ± 16 to 109 ± 17) compared with the clonidine group (mean arterial pressure 100 ± 15 to 110 ± 17 and heart rate 89 ± 19 to 97 ± 19 , $P < 0.05$).

Conclusion: Pretreatment with oral clonidine significantly attenuates MAP and HR changes following bronchoscopy. It is especially beneficial in patients with cardiac disease. (Tanaffos 2005; 4(13): 21-25)

Key words: Fiberoptic bronchoscopy, Blood pressure, Heart rate, Clonidine

INTRODUCTION

Fiberoptic bronchoscopy induces significant hemodynamic alteration. Increase in heart rate, systemic and pulmonary arterial pressure and cardiac indices are seen frequently during bronchoscopy (1, 2).

These changes have been described as a sympathoadrenal response resulting from stimulation of the upper respiratory tract. Although

these responses are usually well tolerated in normal persons, they can have a significant detrimental effect on patients with cardiac disease, preexisting hypertension, and accompanying lung disease (3, 4).

With the additional potential for hypoxemia during bronchoscopy, there is an increased risk for arrhythmia and myocardial ischemia in such patients. Oxygen supply to the heart may be impaired by tachycardia and myocardial oxygen consumption is increased by hypertension and tachycardia, which itself precipitates episodes of myocardial oxygen

Correspondence to: Attaran D

Fax: +98-511-8409612

Email address: d-attaran@yahoo.com

imbalance and ischemia (5, 6).

Clonidine, a centrally acting α_2 agonist has a beneficial effect on the hyperdynamic response to endotracheal intubation. Moreover, it attenuates stress induced sympathoadrenal response to painful stimuli, improves the intraoperative hemodynamic stability and reduces the incidence of perioperative myocardial ischemic episodes (7, 8).

The objective of this double blind, placebo, controlled prospective study was to evaluate the effects of oral clonidine premedication on the hemodynamic alteration during fiberoptic bronchoscopy.

MATERIALS AND METHODS

One hundred patients, scheduled for elective bronchoscopy under local anesthesia participated in this study. The study was approved by our institution's ethics committee. Patients were excluded from the study if they had systolic blood pressure > 180 mmHg, diastolic blood pressure > 110 mmHg, systolic blood pressure < 90 mmHg, heart rate < 50 / min, LBBB, second or greater degree atrioventricular block or previous clonidine medication. Topical anesthesia was achieved by the administration of four puffs of lidocaine spray to the oropharynx and application of 2% lidocaine gel to the nostrils. Bronchoscopy was performed transnasally in the supine position. Supplemental oxygen is not given routinely to all patients undergoing this procedure. If there was a sustained fall in oxygen saturation (<90%), supplemental oxygen was given via nasal cannula. O₂ desaturation <90% occurred in eight patients in clonidine group and six patients in placebo group (NS). The patients were randomly assigned either to receive clonidine or placebo. There were no significant differences in regard to age, underlying diseases and drug medications in the two groups (Table 1). Fifty patients received placebo and fifty patients received

300µg clonidine by the nursing staff, 90 minutes before the procedure.

Table 1. Characteristics of patients.

	Control (N = 50)	Clonidine (N = 50)
Male / Female	27 / 23	25 / 25
Age	62±12	63±10
Smoking	16	18
Underlying disease		
Hypertension	7	8
Diabetes Mellitus	2	2
COPD	4	3
IHD	4	4
Cardio Vascular medication		
Diuretic	3	1
ACE inhibitor	2	4
Ca channel blocker	3	3
Nitrates	5	2

The standard 12 Lead ECG was recorded before and after bronchoscopy.

Intraoperative monitoring consisted of ECG, pulse oximetry and blood pressure. Heart rate and arterial blood pressure measurements were recorded every two minutes until the end of the procedure. The mean arterial pressure was calculated using this formula: $\frac{2 \times \text{DBP} + \text{SBP}}{3}$.

ECG episodes of ischemia were defined as ST or T segment changes.

Statistical analysis: Data are presented as mean values ± SD.

Statistical analysis was carried out using student's t-test and x² test. P-value < 0.05 was considered as statistically significant.

RESULTS

The mean age of patients in clonidine and placebo groups were 63.1 and 62.1 years respectively. Male to female ratio was 1.2. There were no significant

differences in regard to age, sex and duration of procedure in the two groups.

Baseline hemodynamic variables (before the procedure) were not significantly different between the two groups ($p > 0.05$).

During the procedure, patients receiving placebo (control group) showed a significant increase in mean arterial pressure compared with the baseline values and compared with the clonidine group ($p < 0.05$).

No significant increase was observed in mean arterial pressure during the procedure in clonidine group ($p > 0.05$) (Fig 1) and (Table 2).

Table 2. Blood pressure (BP) and heart rate profiles in control and clonidine groups.

	Baseline		After bronchoscopy	
	Control	Clonidine	Control	Clonidine
MAP (mmHg)	97 ± 18	100 ± 15	120.5 ± 17	110 ± 17
Heart rate	90 ± 16	89 ± 19	109 ± 17	97.6 ± 19

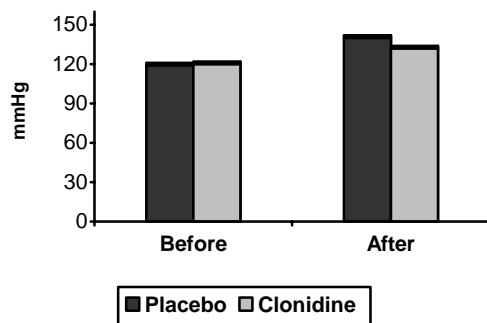


Figure 1. MAP in placebo and clonidine groups before and after bronchoscopy

Patients receiving placebo showed a significant increase in heart rate compared with the baseline and clonidine groups ($p < 0.05$). In contrast patients receiving clonidine exhibited a significant lower heart rate than those in control group ($p < 0.05$)

Figure 2, Table 2.

No arrhythmia was seen before starting bronchoscopy (other than occasional single ectopic beat). Significant ST and T segment changes occurred in two patients in the clonidine group.

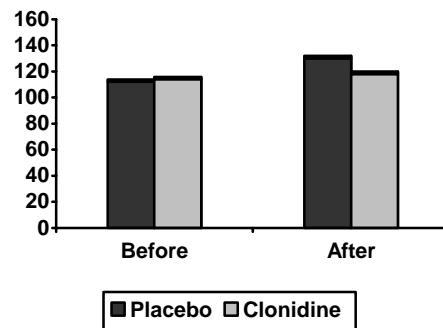


Figure 2. Heart rate in placebo and clonidine groups before and after bronchoscopy

ECG changes occurred in seven patients in the control group. Supraventricular ectopic beat (PAC) occurred in two patients, ventricular ectopic beat (PVC) occurred in three patients, LBBB in one patient and T change in one patient. One patient developed bigeminy PVC during the procedure. Although incidence of ECG changes was higher in control group, there was no significant difference between the two groups ($p > 0.05$). Throughout the study, clonidine side effects such as nausea, vomiting and hypotension were not seen.

DISCUSSION

Manipulation of upper respiratory tract is commonly associated with an increase in heart rate and blood pressure. These effects are associated with an increase in plasma concentration of epinephrine and norepinephrine (2). The increase in blood pressure, heart rate and decrease in O₂ saturation may lead to an imbalance between myocardial O₂ demand and supply, which could result in arrhythmia, myocardial ischemia and eventual

infarction (9, 10).

Previous studies have suggested that premedication with small doses of opioid or clonidine may partially obtund the hemodynamic responses to bronchoscopy or intubation (11). The present study showed that in patients undergoing flexible bronchoscopy, premedication with clonidine could attenuate hemodynamic responses. Our data confirmed the results of the investigations which showed clonidine to be beneficial in blunting reflex tachycardia and hypertension responses associated with intubation and performing rigid bronchoscopy (11, 12). Thus, clonidine premedication may exert a positive effect on cardiac O₂ delivery and consumption balance (11).

The risk of myocardial ischemic episodes as shown by ST and T segment deviation, can be reduced by oral premedication with clonidine. In patients undergoing vascular surgery, Stuhmeier et al. found that premedication with oral clonidine reduced the incidence of perioperative myocardial ischemic episodes from 39% (placebo group) to 24% (clonidine group) (13). In the present study, seven patients (14%) in control group had electrocardiographic changes (arrhythmia and ischemia). These events were accompanied by significant rises in heart rate and blood pressure. There were no significant differences in regard to ischemic events and arrhythmia in the two groups ($p > 0.05$). Perhaps a prospective study with long duration of cardiac monitoring after bronchoscopy is necessary to determine whether the effect of clonidine on the incidence of ischemia and arrhythmia is significant.

In conclusion, results of this study show that small doses of clonidine can reduce the incidence of hemodynamic instability during bronchoscopy and routine use of clonidine as premedication may benefit the patients with cardiovascular and hypertensive diseases.

REFERENCES

1. Matot I, Kramer MR, Glantz L, Drenger B, Cotev S. Myocardial ischemia in sedated patients undergoing fiberoptic bronchoscopy. *Chest* 1997; 112 (6): 1454- 8.
2. Lundgren R, Haggmark S, Reiz S. Hemodynamic effects of flexible fiberoptic bronchoscopy performed under topical anesthesia. *Chest* 1982; 82 (3): 295- 9.
3. Hill AJ, Feneck RO, Underwood SM, Davis ME, Marsh A, Bromley L. The haemodynamic effects of bronchoscopy. Comparison of propofol and thiopentone with and without alfentanil pretreatment. *Anaesthesia* 1991; 46 (4): 266- 70.
4. Wark KJ, Lyons J, Feneck RO. The haemodynamic effects of bronchoscopy. Effect of pretreatment with fentanyl and alfentanil. *Anaesthesia* 1986 ;41(2):162-7.
5. Fleicher LA. Perioperative myocardial ischemia and infarction. *Int Anesthes Clin* 1994; 4, 1-15.
6. Gill NP, Wright B, Reilly CS. Relationship between hypoxaemic and cardiac ischaemic events in the perioperative period. *Br J Anaesth* 1992; 68 (5): 471- 3.
7. Mikawa K, Maekawa N, Nishina K, Takao Y, Yaku H, Obara H. Efficacy of oral clonidine premedication in children. *Anesthesiology* 1993; 79 (5): 926- 31.
8. Kulka PJ, Tryba M, Zenz M. Dose-response effects of intravenous clonidine on stress response during induction of anesthesia in coronary artery bypass graft patients. *Anesth Analg* 1995; 80 (2): 263- 8.
9. Matot I, Kramer M. Sedation for fiberoptic bronchoscopy: alfentanil-propofol vs pethidine - midazolam, *Jou Bronchol*; 1999, 6, 74-7.
10. Slogoff S, Keats AS. Does perioperative myocardial ischemia lead to postoperative myocardial infarction? *Anesthesiology* 1985; 62 (2): 107- 14.
11. Longnecker DE. Alpine anesthesia: can pretreatment with clonidine decrease the peaks and valleys? *Anesthesiology* 1987; 67 (1): 1- 2.
12. Matot I, Sichel JY, Yofe V, Gozal Y. The effect of clonidine premedication on hemodynamic responses to microlaryngoscopy and rigid bronchoscopy. *Anesth Analg* 2000; 91 (4): 828- 33.
13. Stuhmeier KD, Mainzer B, Cierpka J, Sandmann W, Tarnow J. Small, oral dose of clonidine reduces the incidence of intraoperative myocardial ischemia in patients having vascular surgery. *Anesthesiology* 1996; 85 (4): 706- 12.