

Tanaffos (2009) 8(1), 14-22

©2009 NRITLD, National Research Institute of Tuberculosis and Lung Disease, Iran

Anthracotic Airways Disease: Report of 102 Cases

Kazem Amoli

Department of Medicine, Tehran University of Medical Sciences, TEHRAN-IRAN.

ABSTRACT

Background: Numerous causes can lead to chronic inflammatory lesions of the lower respiratory airways including those recognized as chronic obstructive pulmonary disease (COPD), of which tobacco smoke has been established. Air pollution and smokes from indoor and outdoor origins are among the possible causes. However, further investigations are required on this issue.

Materials and Methods: Amongst those who underwent diagnostic bronchoscopy in the pulmonary endoscopy unit, Tehran University of Medical Sciences from April 1975 to March 2000, 102 patients revealed generalized chronic changes of the airways with significant anthracotic deposits. Their clinical manifestations, demographic data, radiological, biopsy and bronchial washing findings were evaluated and compared with a similar number of contemporary cases without anthracotic lesions but with a variety of established pathologies.

Results: Clinically, the patients with anthracotic airway lesions were already respiratory cripples. Females (n=60) had been exposed to long-term indoor smoke inhalation while baking home-made bread. Males (n=42) had a variety of occupations that entailed heavy smokes. Those without bronchial anthracosis had no similar histories.

Conclusion: Long-term smoke inhalation can cause chronic anthracotic bronchopathies leading to respiratory invalidism. The problem seems to be extensive and has not confined to Iran. Further worldwide studies are required to address different aspects, including prevention of these ailments. (*Tanaffos* 2009; 8(1): 14-22)

Key words: COPD, Anthracosis, Air pollution, Anthracotic bronchitis, Indoor air pollution

INTRODUCTION

Chronic bronchial inflammatory lesions, both as a part of chronic obstructive pulmonary disease (COPD) or otherwise are universal. Tobacco smoking has been established as the main etiologic factor and air pollution from outdoor and indoor origins is also incriminated although the latter needs to be more materialized.

Patients were usually females from rustic population who used to cook or bake indoors while inhaling smokes from the combustion of wood or dung. However, these studies mainly addressed the clinical (1-5) or pulmonary function tests (6,7), and radiologic features (8,9). The pathology of the lesions as could be visualized by bronchoscopy was not evaluated except in one report (8). The microscopy of the lesions had not been described either.

In our study (Iran), chronic airways disease was

Correspondence to: Amoli K

Address: 448, Asadabadi Ave., Tehran 14368, Iran.

Email address: k_amoli@yahoo.com

Received: 23 November 2008

Accepted: 1 February 2009

found in individuals who had never smoked and used to live in unpolluted areas. Bronchoscopy of these patients revealed widespread chronic inflammatory changes along with black areas in the airway walls (10,11). History taking showed that they had been chronically exposed to smokes from a variety of sources. In women, indoor inhalation of smoke during household cooking was suspected while males had histories of various occupations associated with smoke production or carbonaceous dusts.

This article aimed to study the possible role of chronic smokes inhalation in the etiology of inflammatory bronchopathies characterized by anthracotic lesions of the airway walls.

MATERIALS AND METHODS

From April 1975 to March 2000, of patients referred to the pulmonary endoscopy unit at Tehran University of Medical Sciences, 102 were found to have chronic inflammatory changes and anthracotic deposits in their airways. Patients were clinically examined, their bronchoscopic results were evaluated and if the biopsy sample taken during the procedure was suitable, histopathological examination was performed. Chest x-rays were available for all cases. Those admitted after 1991, also had a CT-scan if indicated. Respiratory function tests were limited to forced vital capacity (FVC) and forced expiratory volume in 1 second (FEV₁). Farafan spirometer (Farafan Co., Tehran) was used. The figures were compared with the normal values obtained from an Iranian study (13,14). Olympus (Olympus Optical Co, Tokyo, Japan) or Pentax (Asahi Optical Co, Tokyo, Japan) video-bronchofiberscopes were used. Bronchial aspirates were obtained for both cytology and bacteriology testing. Biopsies were carried out with standard small biopsy needles. Diagnostic thoracotomy was only performed in one of the females of the anthracotic group.

Controls were 103 patients who had other

diseases with no black deposits in their bronchi. Similar diagnostic procedures were performed in these patients including thoracotomy in 5 cases (1 male and 4 females) done under similar circumstances and the results were compared with the anthracotic cases. These patients had been referred for diagnostic problems. Anthracotic deposits were detected incidentally. No patient had undergone bronchoscopy primarily to search for these particular lesions.

RESULTS

Demographic characteristics of both groups (those who demonstrated anthracosis on their airways, and those without black deposits in their bronchi), are shown in Table 1. Although both groups were referred for diagnostic problems, the following features could characterize those with anthracotic lesions: First, these patients, male or female, were older, mainly middle-aged and elderly, who lived under the care of their offspring. Second, while all the patients without anthracosis happened to be town-dwellers, almost half the males and all females in the anthracotic group came from the country. Third, all female patients with anthracosis were full-time housewives; only 6.6% of them were engaged in additional outdoor jobs while 40% of the control females were in civil service. With the males also, the contrast was significant because those with anthracosis were less educated compared with their counterparts who were mainly white-colored. However, regarding tobacco smoking habits, there was almost no difference between the two groups. Finally, the anthracotic patients were physically smaller and thinner (Table 2) as could be characterized by body mass index (BMI).

All patients had been referred because of symptoms; cough was the most frequent symptom in both groups and genders followed by exertional dyspnea in females and sputum production in males.

Fever, chest discomfort, haemoptysis, wheezing, weight loss and colds were other complaints in decreasing order of frequency. Arthralgia occurred in the control patients. Altogether, the females with anthracosis had milder symptoms than others.

Table 1: Demography of the patients with anthracotic airways lesions compared with controls

Variables	Case	Control
Gender		
Men	42	43
Women	60	60
Age, mean (range)		
Men	60 (29-77)	40.5 (31-72)
Women	61.8 (45-77)	44.7 (14-73)
Origin, rustic (%)		
Men	47.6	0
Women	100	0
Origin, urban (%)		
Men	52.4	100
Women	0	100
Occupations (No.)		
Men Workers	31	0
Men Business	3	8
Men Civil service worker	3	35
Men Farmers	6	0
Women Housewives	56	36
Women Outdoor jobs	4	24
Ever smokers (%)		
Men	55.4	55.5
Women	9	11.6

Table 2. Body mass index (BMI) of patients with airways anthracosis compared with to controls (the figures represent the percentage of the individuals in each group)*

BMI Category	Anthracosis		No anthracosis	
	Men	Women	Men	Women
<18.5 (underweight)	30.7	22.7	5	0
18.5-24 (normal)	43.2	52.2	50	50
25-27 (overweight)	26.9	27.2	40	31
30-34 (obese I)	0	0	5	17.2
35-39 (obese II)	0	0	0	1.7

*Categories adapted Xavier Pi-Sunyer, F, obesity.

In: Goldman, L, Claude Bennett, J, Eds. Cecil Textbook of Medicine, Philadelphia, 2000, pp 1155.

Bronchology

In anthracotic patients, generalized swelling and congestion were found in the airways with infiltration, thickening, bulging and tortuosity. Luminal narrowing ensued so that the bronchoscope could not pass through and occlusion occurred, notably in the right middle lobe. Black mucous or mucopurulent secretions appeared in moderate quantities from both sides and the openings of the mucous glands were widened. Characteristically, there were multiple plaques of black deposits (Figure 1) not only on the surface of the airways, mainly in the lobar and segmental divisions, but also in the trachea and subsegmental branches. The epithelium was slightly raised and fragile with a tendency to bleed.

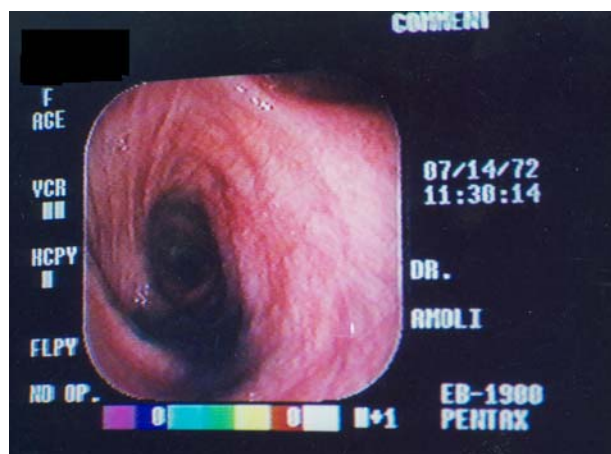

Figure 1: Bronchoscopic view of a 50-year-old rustic non-smoker female who was referred with cold, fever, cough, sputum, dyspnea and wheezing. Anthracotic deposits were seen at the entrance of right main bronchus extending to the right upper lobe. Note the mucus particles protruding from the widened submucosal glands openings. She had a long history of household bakery using dung and wood, causing a heavy smoke.

The findings of the control patients are not dealt with here as their diagnoses are mentioned in Table 3; the main point to be emphasized is that they had no anthracotic lesions.

Table 3. Disorders diagnosed in patients with anthracotic airway lesions and in those without anthracosis (control patients).

	With anthracosis	Control patients
Total No.	102	103
Men	42	43
Anthracotic lesions	42	0
Neoplasms	2	18
ILD	0	10*
Pneumoconiosis	7	0
Other bronchopathies	0	7**
Tuberculosis	9	6
Lung abscess	0	2
Women	60	60
Anthracotic lesions	60	0
ILD	1*	25**
Tuberculosis	18	13
Neoplasms	0	11
Other bronchopathies	1	11***

ILD: interstitial lung disease

* Includes 7 cases with sarcoidosis

** Two with asthma

◆ Not specified

◆◆ Includes 22 cases with sarcoidosis

◆◆◆ Six with asthma

Pathology

In the anthracotic group, bronchial washings showed free black particles with normal or degenerated cells and few inflammatory cells. Malignant cells were not detected. Biopsy samples revealed infiltration of non-specific mononuclear inflammatory cells, mainly macrophages, and to a lesser extent, polymorphonuclears, eosinophils, lymphocytes and plasma cells both in the epithelium and stroma with edema and granulation tissue. The epithelium; however, was intact; the pseudostratified arrangement with ciliated and goblet cells being preserved. Only occasional squamous metaplasia and dysplasia were noted. Congestion, hypervascularization, thickening of the basement membrane and fibrosis were also reported. The most significant findings were the intracellular and extracellular black particles observed in the

epithelium and stroma (Figure 2). Granulomas were not found. These findings are in contrast with the cigarette-induced chronic bronchitis which is characterized by the multiplication of goblet cell, hypertrophy of submucosal glands, increase of the Reid index, epithelial dysplasia, a tendency towards neoplasia; and with hypersensitivity pneumonitis which is characterized by granuloma formation.

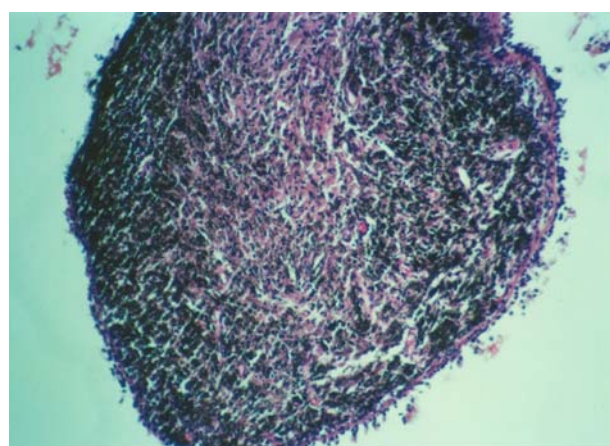


Figure 2: Biopsy sample taken from the anthracotic entrance of the right middle lobe in a 65 year-old nonsmoker rustic female complaining of dyspnea, recent fever, rigors and sweating. Abundant anthracotic epithelial and stromal pigments phagocytosed by macrophages are seen. Free black particles were significant. She died of respiratory failure 7 months later.

Respiratory function tests

Reliable figures for VC and FEV1 could be obtained only in 39 cases with airways anthracosis and 82 control patients. The corresponding results are shown in Table 4. Those with anthracotic lesions had a more obstructive pattern in spirometry than their counterparts.

Table 4. Pattern of respiratory function in cases with airways anthracosis compared with control patients.

Pattern (%)	Anthracotics		Controls	
	Men	Women	Men	Women
Obstructive	62.5	60.8	45.1	29.4
Restrictive	31.2	30.4	45.1	41.2
Normal	6.2	8.8	9.8	29.4

Radiology

Radiologic findings in the control group were related to their specific diseases (Table 3) that are irrelevant to the original topic of the present article. All the anthracotic patients had abnormal chest x-rays. The basic findings were streaky shadows along the bronchovascular markings in paracardiac and parahilar regions that obscured the cardiac borders (Figure 3). Additionally, in relation to the associated diseases (vide infra) a variety of fixed or transient opacities occurred due to consolidations, fibrosis, atelectasis and tracheal deviation. Hilar adenopathy was not outstanding. CT-scan complemented the chest x-ray findings.

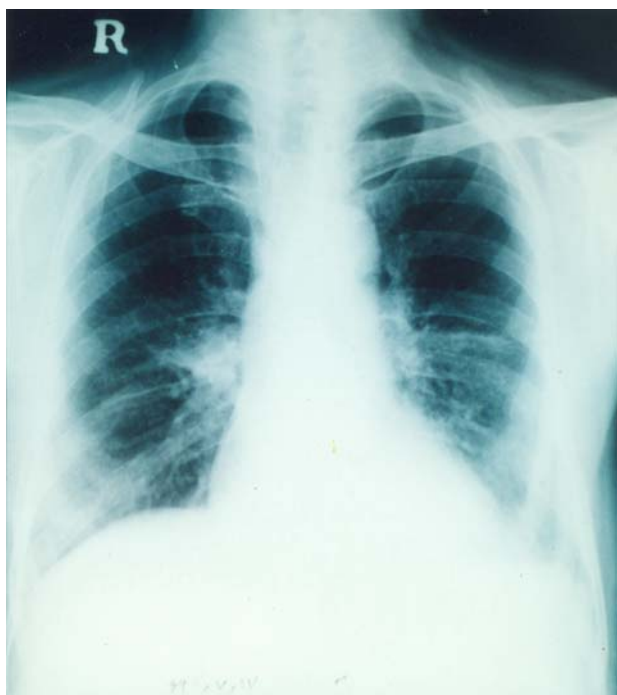

Figure 3: Chest X-ray of a 75 year-old nonsmoker male farmer who worked as a cook, baker and gardener. Note the hilar opacities and streaky paracardiac shadows mainly on the right side with downward displacement of the interlobar fissure. He used to enjoy burning twigs and sweepings in his garden for both heating and disposal. He became gradually dyspneic on walking uphill. Widespread anthracotic plaques were found on bronchoscopy

Associated disorders in cases with airways anthracosis:

In addition to 27 cases complicated with tuberculosis (including 18 women) the following associated disorders were recognized in men: seven cases with pneumoconiosis, four with hypertension, one with asthma and one with Parkinson's disease. Among women, eight patients had hypertension, four had diabetes mellitus, two had bronchiectasis and one with systemic lupus erythematosus was detected.

Management and follow-up

The patients with anthracotic airway lesions had a stationary and inactive course being interrupted by acute attacks. Those with tuberculosis were treated successfully using standard short-course chemotherapy. Other infections were treated with antibiotics. Many patients were lost in the follow-up but information could be acquired up to 13 years, so far the longest survival since the patient underwent bronchoscopy.

DISCUSSION

The present report is a compilation of 102 patients who were found to have chronic anthracotic bronchopathies. The majority of them came from unpolluted areas and never smoked cigarettes. Observation of free black particles in bronchial washings and airway wall biopsies suggested long-term inhalation of smokes. The patients; however, did not volunteer to mention about their past history as they did not think of any relevance to their present illness. Direct questioning; however, revealed that they had been exposed to smoke and carbonaceous particulates in various ways. Sources of air pollution were found to be the followings:

- A. The female patients used to bake household bread when they were young and active, using indoor ovens situated in small enclosures with little or no

ventilation (Figure 4). Dung or wood was used and the area became filled with smoke. Anthracosis and inflammation of the airways built up gradually and the patient became incapacitated by intervening acute respiratory infections and additional disorders.

- B. In men a variety of occupations seemed to be the source of air pollution. Amongst them were seven miners who long ago used to inhale uncombusted coal particles as well as the soot from materials used to produce light in their workplace. Other workers were engaged in jobs involving cement, asphalt and kilns. Aqueduct-workers are those who dig or regularly clean the underground aqueducts i.e. the kilometers-long subterranean waterway that drains water from higher sources down to residential centers for both drinking and irrigation (15). There is no ventilation facility in the tubes where kerosene or carbide is used for light; hence the worker becomes exposed to both smoke and dust. Farmers had occasional smoke inhalation for example when burning twigs and sweepings for heating and disposal, giving rise to heavy smoke. Businessmen and those in the civil service could not recall a clear-cut source of the exposures.



Figure4: A small room for baking bread with no windows. All the walls and the tools are covered with soot. A column of sunshine demonstrates the thickened dust-filled air while the fire glows out from the oven.

Is there a connection between the past history of these patients with the anthracotic lesions? Of course none of them had been followed up prospectively from the beginning of their exposures to smoke down to their present state. Nevertheless, there are objective reasons to presume the relationship. First is the observation of the actual condition of the environment they used to work. Several localities were visited around the country where, as mentioned above, small enclosures are used by the rustic housewives for bakery during the cold winters. The place is blackened by the smoke (Figure 4) which, although unpleasant, is not irritant enough to keep off the individual. There are no windows and the walls are covered by a thick deposition of soot that is also easily accessible to the respiratory tract of the baker. The same circumstances apply to the working places of the male patients. For example, tunnels of mines and road industry were found to have almost no visibility due to smoke and all the framework was covered with soot. Unfortunately, the preventive measures are not efficiently followed.

Second, free black particles were found in the bronchial washings from the anthracotic lesions.

Third, black pigmented inclusions prevailed intracellularly in macrophages and in the epithelial cells as well as in the extracellular stroma (Figure 2).

On the other hand, all the control patients had no anthracosis although they had inflammatory mural changes of their airways in addition to the specific pathologies. The majority of the latter group lived in highly polluted towns, about 2/3 of them in Tehran. Further, 55.5% of the males were cigarette smokers. However, these two important agents i.e. tobacco smoke and general atmospheric pollution were not enough to bring about anthracosis in the control patients.

Thus, long-term smoke inhalation can lead to

chronic inflammatory changes with serious airways distortion and should be regarded as an independent cause of disabling pneumopathies with the resultant COPD. As the local defense impairs, colonization of the airways by various microorganisms set the stage for repeated acute episodes. Moreover, tuberculosis appears to be a major complication as the prevalence of its active form among the patients with anthracotic lesions was even higher than in the control group, who were especially suspected of having the disease. The increased proportion of tuberculosis was described in 1994 by the author (11), and other reports confirmed this relationship (16-19). This is because of the disordered systemic and local defense; generally, the anthracotic subjects were weak and poor individuals with smaller frames as shown in Table 2. Local defense was disturbed by the enormous macroscopic and histological changes that prevent the clearance of inhaled *Mycobacterium tuberculosis* and other germs; helping their multiplication and resulting in development of disease. Charcoals are exogenous particles and are not produced inside the body. Anthracosis is not the cause of tuberculosis but is complicated by the disease. On the other hand, tuberculosis is not the cause of anthracosis; the body cannot produce high temperatures to make charcoal particles. Smoke-related anthracotic lesions do not occur only in Iran. Similar conditions prevail in the neighboring countries and in the "Third World" (20). In addition to the author's report (11), several other papers have been published from Iran (21,22). Although the peculiar aspects have not been demonstrated in most reports, chronic airways disease in relation to indoor pollution has been found in many countries including Nepal (1), China (2,3) India (4,5,23), Saudi Arabia (24), Mozambique (25), Columbia (26), Guatemala (27), Bangladesh (28), Turkey (18), Greece (29), and

Indonesia (personal communication with WHO). The multitude of the patients is soaring (30).

The problem has already been exposed by the WHO (31, 32). With increasing number of immigrants from the "developing countries" to Europe and North America, cases of these categories may refer to the local physicians in the developed countries, usually when an acute episode supervenes (28). Unnecessary invasive diagnostic procedures may be contemplated due to unfamiliarity with the problem. Complications such as active tuberculosis, however, should be considered.

Diagnosis of anthracotic airways disease is based on the familiarity with the condition, direct inquiry into the past history, clinical examination, radiologic findings, and eventually by bronchoscopy, pathology, and bacteriology. Bronchoscopy may be indicated mainly to rule out or confirm other diseases or complications but may not be demanded if the history clearly confirms the previous exposure.

In conclusion, chronic smoke inhalation, both indoors and occupationally related, seems to be an important cause of chronic airways disease leading to respiratory failure. Extensive studies are required to elucidate the various aspects of the problem including the nature of the inhaled particles and the aerodynamic properties of the dusts' deposition in particular areas of air passages. Other aspects such as the epidemiology, pathology, bacteriology, education and modernization of the lifestyles are expected to protect the masses of people already at risk of growing towards respiratory invalidity.

Acknowledgements

Many thanks to the pathologists M.R. Baquerzadeh, S. Shariat, A. Gransar, and the bacteriologists K. Qazi-saidi, A. Zarifi, whose reports expanded the clinical significance of this work.

REFERENCES

1. Pandey MR. Domestic smoke pollution and chronic bronchitis in a rural community of the Hill Region of Nepal. *Thorax* 1984; 39 (5): 337- 9.
2. Xu X, Wang L. Association of indoor and outdoor particulate level with chronic respiratory illness. *Am Rev Respir Dis* 1993; 148 (6 Pt 1): 1516- 22.
3. Zhou X, Jin Y, He X. A study on the relationship between indoor air pollution and chronic obstructive pulmonary disease in Xuanwei County. *Zhonghua Yu Fang Yi Xue Za Zhi* 1995; 29 (1): 38- 40.
4. Dhar SN, Pathania AGS. Bronchitis due to biomass fuel burning in North India: "Gujjar Lung", An extreme effect. *Semin Resp Med* 1991; 12: 69- 73.
5. Qureshi KA. Domestic smoke pollution and prevalence of chronic bronchitis/asthma in a rural area of Kashmir. *Indian J Chest Dis Allied Sci* 1994; 36 (2): 61- 72.
6. Behera D, Jindal SK, Malhotra HS. Ventilatory function in nonsmoking rural Indian women using different cooking fuels. *Respiration* 1994; 61 (2): 89- 92.
7. Behera D. An analysis of effect of common domestic fuels on respiratory function. *Indian J Chest Dis Allied Sci* 1997; 39 (4): 235- 43.
8. Kim HY, Im JG, Goo JM, Kim JY, Han SK, Lee JK, Song JW. Bronchial anthracofibrosis (inflammatory bronchial stenosis with anthracotic pigmentation): CT findings. *AJR Am J Roentgenol* 2000; 174 (2): 523- 7.
9. Saini Natal R, Kuchers S, et al. Wood smoke exposition unusual cause of military mottling on Chest X-ray. *Indian J Chest Allied Sci* 2003; 45: 276-276.
10. Sandoval J, Salas J, Martinez-Guerra ML, Gómez A, Martinez C, Portales A, et al. Pulmonary arterial hypertension and cor pulmonale associated with chronic domestic woodsmoke inhalation. *Chest* 1993; 103 (1): 12- 20.
11. Amoli K. Bronchopulmonary complications of indoor pollution in Iranian rustic population. *Acta Medica Iranica* 1994; 32: 35- 41.
12. Amoli K. Bronchopulmonary disease in Iranian housewives chronically exposed to indoor smoke. *Eur Respir J* 1998; 11 (3): 659- 63.
13. Masjedi MR, Faqihi AH, Johnson DC. Measurement of standard spirometric figures in healthy nonsmokers. *Daru-va-Darman* 1988; 5-15 (in Persian).
14. Health and Disease Assay. Bulletin of the Public Health 1993. Tehran University of Medial Sciences (in Persian).
15. Amoli K. Aqueduct-workers lung. *J of Medical Council of Islamic Republic of Iran* 1998; 15: 133-8 (in Persian), English abstract: 221.
16. Towhidi M, Keshmiri M, Attaran, D. Tuberculous bronchostenosis presenting as anthracofibrosis. *Eur Respir J* 2001; 18 suppl. 33: 218s.
17. Long R, Wong E, Barrie J. Bronchial anthracofibrosis and tuberculosis: CT features before and after treatment. *AJR Am J Roentgenol* 2005; 184 (3 Suppl): S33- 6.
18. Trum T, Gungor G, Ozamen J, et al. Bronchial anthracosis in patients exposed to biomass smoke. *Turkish Respir J* 2007; 8: 048- 051.
19. Hemmati SH, Shahriar M, Molalaei NA. What causes anthracofibrosis? either tuberculosis or smoke. *Pak J Med Sci* 2008; 24: 398.
20. Smith KR, Samet JM, Romieu I, Bruce N. Indoor air pollution in developing countries and acute lower respiratory infections in children. *Thorax* 2000; 55 (6): 518- 32.
21. Najafizadeh, K, Zahirifard S, Mohammadi, F et al. Bronchial anthracofibrosis or anthracotic bronchitis. *Tanaffos* 2003; 2: 7- 11.
22. Mirsadraee P. Anthracosis of Lung: evaluation of potential underlying cause. *Journal of bronchology* 2005; 12: 84-7.
23. Dutt D, Srinivasa DK, Rotti SB, Sahai A, Konar D. Effect of indoor air pollution on the respiratory system of women using different fuels for cooking in an urban slum of Pondicherry. *Natl Med J India* 1996; 9 (3): 113- 7.
24. Døssing M, Khan J, al-Rabiah F. Risk factors for chronic obstructive lung disease in Saudi Arabia. *Respir Med* 1994; 88 (7): 519- 22.

25. Ellegård A. Cooking fuel smoke and respiratory symptoms among women in low-income areas in Maputo. *Environ Health Perspect* 1996; 104 (9): 980- 5.
26. Dennis RJ, Maldonado D, Norman S, Baena E, Martinez G. Woodsmoke exposure and risk for obstructive airways disease among women. *Chest* 1996; 109 (1): 115- 9.
27. Bruce N, Neufeld L, Boy E, West C. Indoor biofuel air pollution and respiratory health: the role of confounding factors among women in highland Guatemala. *Int J Epidemiol* 1998; 27 (3): 454- 8.
28. Gold JA, Jagirdar J, Hay JG, Addrizzo-Harris DJ, Naidich DP, Rom WN. Hut lung. A domestically acquired particulate lung disease. *Medicine (Baltimore)* 2000; 79 (5): 310- 7.
29. Tzanakis N, Kallergis K, Bouros DE, Samiou MF, Siafakas NM. Short-term effects of wood smoke exposure on the respiratory system among charcoal production workers. *Chest* 2001; 119 (4): 1260- 5.
30. Amoli K. The study of 819 cases of anthracotic airway disease. *Journal of Medical Council of Islamic Republic of Iran* 2004; 21: 259-65 (in Persian), English abstract: 338.
31. de Koning HW, Smith KR, Last JM. Biomass fuel combustion and health. *Bull World Health Organ* 1985; 63 (1): 11- 26.
32. Chen BH, Hong CJ, Pandey MR, Smith KR. Indoor air pollution in developing countries. *World Health Stat Q* 1990; 43 (3): 127- 38.