

Tanaffos (2010) 9(3), 28-32

©2010 NRITLD, National Research Institute of Tuberculosis and Lung Disease, Iran

Surgical Treatment of Chest Wall Tuberculosis

Manuchehr Aghajanzadeh, Zahra Pourrasouli, Gilda Aghajanzadeh, Sarrah Massahnia

Department of Thoracic Surgery, Guilan University of Medical Sciences (GUMS), Razi Hospital, RASHT- IRAN.

ABSTRACT

Background: Tuberculosis remains a formidable challenge to health care providers in developing countries and chest wall tuberculosis is a rare entity. Its clinical presentation may resemble a pyogenic abscess or chest wall tumor. There is still controversy regarding the diagnosis and treatment of chest wall tuberculosis.

Materials and Methods: During a 10-year period (1998–2009), 12 cases with chest wall tuberculosis were managed by our team. Patients' medical records were retrospectively reviewed. After confirming the diagnosis by histopathological examination, patients underwent surgical management.

Results: There were 8 male and 4 female patients. Patients' age ranged from 4 to 60 years. Eight patients had a fluctuating abscess and 4 had a chest wall mass. Surgical procedure was drainage along with debridement in 6 patients, wide debridement along with rib resection in 2 patients and wide debridement along with chest wall resection and reconstruction in 4 patients. Recurrence of cold abscess and fistula formation were detected in 2 patients after a follow-up of 1 to 5 years. Outcome of patients with chest wall tuberculosis was good.

Conclusion: chest wall tuberculosis mimics symptoms and signs of chest wall tumors or abscesses. The combination of symptoms and radiographic findings suggests the diagnosis of tuberculosis. Wide debridement and resection are shown to have lower rates of fistula formation, sinus formation and recurrence. Medical treatment must be started immediately after surgery. (Tanaffos2010; 9(3): 28-32)

Key words: Chest wall, Tuberculosis, Abscess, Mass

INTRODUCTION

Tuberculosis remains a formidable challenge to health care providers in developing countries. Incidence of tuberculosis is still high in developing countries despite anti-tuberculous treatments.

Although lungs are the main target in primary infection, extra pulmonary tuberculosis constitutes 15–20% of all tuberculosis cases (1,2). *Mycobacterium tuberculosis* can cause a soft tissue infection of the chest wall. Bone and joint involvement is rare, accounting for only 2% of all cases (1, 2). In a case series of skeletal tuberculosis, spine was involved in 50%; pelvis in 12%; hip and femur in 10%; knee and tibia in 10%, and ribs in 7 % of cases respectively. (3) Rib destruction may or may

Correspondence to: Aghajanzadeh M

Address: Respiratory Diseases & TB Research Center, Guilan University of Medical Sciences (GUMS), Razi Hospital, Rasht, Iran.

Email address: maghajanzadeh2003@yahoo.com

Received: 22 April 2010

Accepted: 3 June 2010

not be present. Tuberculosis is the second cause of rib destruction after metastasis (2, 3). Differentiation of rib tuberculosis from cold abscess or tumor of the chest wall may be difficult. Although anti-tuberculous drugs and some surgical procedures have been used for the treatment of chest wall tuberculosis, there is still controversy regarding optimal therapeutic management (2,5,6).

The purpose of this case series was to discuss the clinical features, diagnostic workup, and role of surgery in the management of chest wall tuberculosis.

MATERIALS AND METHODS

In this case series, we retrospectively reviewed the data of 12 patients with chest wall tuberculosis who were treated from 1998 to 2009. Evaluation included: patients' signs and symptoms, PPD intradermal test, sputum for BK, location, chest X-ray and chest CT-scan. Initially, aspiration (FNA and tru-cut needle biopsy) of the chest wall mass was performed. Microbiological and cytological examination and acid-fast bacilli (AFB) investigation were carried out on the aspirated fluid. Tissue biopsy was not performed at the time of initial aspiration. When aspiration was not diagnostic, an incisional biopsy was performed. Diagnosis was established if one or a combination of the following conditions was present: Caseous granulomatous necrosis or Langhans giant cell on surgical debridement or biopsy specimens, or identification of tuberculosis. After confirming the diagnosis, patients underwent surgical management followed by medical therapy.

RESULTS

There were 8 male and 4 female patients. Patients were in the age range of 4 to 60 years. There was a past medical history of pulmonary tuberculosis in five cases. Immunodeficiency syndrome (HIV

infection) test was done which was negative in all 12 patients. All patients were symptomatic. Other signs and symptoms are present in Table 1. Chief complaint of all patients was a chest wall mass. On physical examination the chest wall mass was soft and fluctuating in 8 but firm in 4 patients. Diagnostic imaging was chest X-ray and computed tomography. Pulmonary parenchyma was abnormal on chest X-ray in 3 patients. Computed tomography of patients was abnormal in 6 cases from the standpoint of pulmonary parenchyma and mediastinum (Figures 1 and 2) and included mediastinal lymph node enlargement, rib destruction, pleural nodule and pulmonary parenchymal infiltration. In 8 patients, a well-defined soft tissue mass with central attenuation and peripheral rim enhancement was present on computed tomography.

Definitive diagnostic workup was through FNA and tru-cut needle biopsy in 3 cases and open biopsy in 9 cases. Histopathological examination revealed caseous granulomatous inflammation in 7 cases and Langhans giant cell with caseous granulomatous inflammation in 5 cases. BK was positive in 3 cases after aspiration and culture was positive for BK in 4 cases.

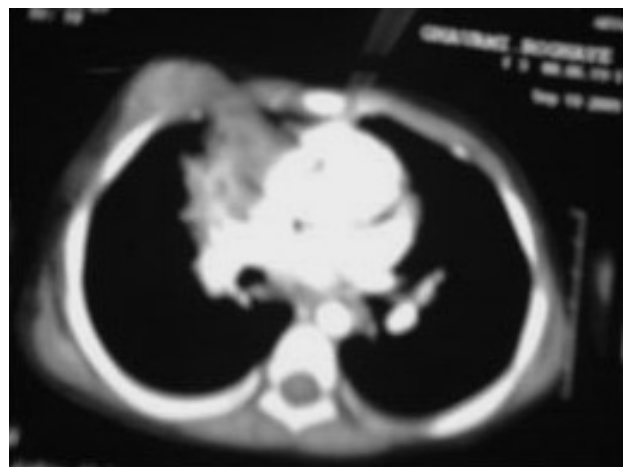


Figure 1. CT-scan of a patient with chest wall tuberculosis and mediastinal involvement.

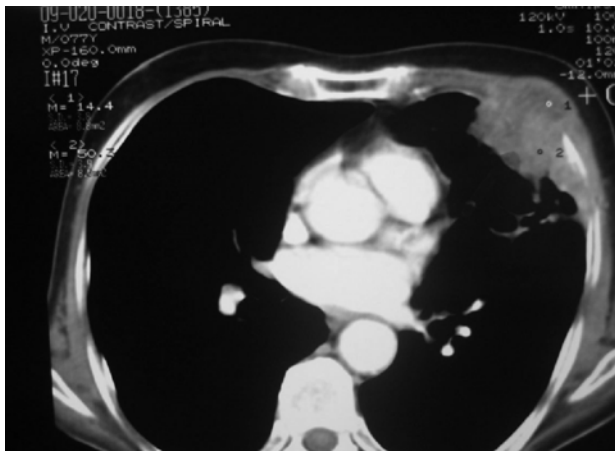


Figure 2. CT-scan of a patient with chest wall tuberculosis and rib destruction.

After pathologic confirmation, all patients underwent surgery and anti-tuberculous medical treatment. Surgical procedures were drainage and debridement in 6 patients, wide debridement with rib resection in 2 patients and wide debridement with

chest wall resection and reconstruction in 4 patients. We put a catheter in abscess cavity after drainage. There were postsurgical fistula and sinus tract in 2 patients from the drainage and debridement group 4 weeks later which healed following the administration of anti-tuberculosis medication. Wound infection occurred in 3 patients and recurrence occurred in one patient in drainage and debridement group after 1-5 years follow up. All patients received anti-tuberculous therapy with the initial four-drug regimen (isoniazid, rifampicin, pyrazinamide, and ethambutol) for 3 months followed by two drugs.

Medical treatment continued for 9 months in 6 patients, 6 months in 4 patients and 12 months in 2 patients. Incidence of fistula, sinus tract formation and recurrence was higher in drainage and debridement group.

Table 1. Data of patients with chest wall tuberculosis.

Case	Age (Yrs.)	Sex	Local Pain	Local erythema	Fluctuation	Duration (months)	Location	Fever	Local tenderness
1	52	F	+	-	+	5	Posterior	+	+
2	35	M	+	-	+	2	Lateral	-	-
3	4	M	+	+	-	3	Anterior	-	+
4	45	F	+	-	+	6	Anterior	+	-
5	38	M	+	-	-	4	Posterior	-	+
6	42	M	+	-	+	3	Posterior	-	-
7	24	F	+	-	+	2	Lateral	+	+
8	22	M	+	+	+	4	Posterior	-	-
9	58	M	+	-	-	5	Lateral	-	+
10	42	F	+	-	+	6	Posterior	+	-
11	32	M	+	-	+	2	Anterior	-	+
12	46	M	+	-	-	1	Anterior	-	+

DISCUSSION

Chest wall tuberculosis is usually presented with a painless mass. The palpable mass is frequently cystic or soft, and may fluctuate on physical examination. Local tenderness or erythema may be present but this sign in fact is suggestive of super infection of cold abscess (2, 5, 6). Seven of our patients presented with local tenderness. Four of our patients had a soft abscess. Cold abscesses of chest wall are generally solitary. In a case series of 18 patients with chest wall cold abscesses, 89% of them were solitary (7). Three of our patients had one abscess and the remainder had 3 abscesses. Chest wall tuberculosis may occur through two mechanisms: 1- hematogenous dissemination, and 2- direct extension from the lymphadenitis of the mediastinum (8). Location of abscess in our patients was anterior chest wall in 4 patients, posterior thoracic wall in 5 patients and lateral in 3 patients. More than half the lesions of rib tuberculosis had no evidence of rib destruction. Four patients had past medical history of tuberculosis.

In Faure's report, 83% of patients had a positive history of tuberculosis and there was active pulmonary tuberculosis in 33% of cases (8). Active pulmonary tuberculosis was not seen in our patients. The preoperative diagnosis of chest wall cold abscess is difficult (5, 6, 9, 10). The diagnosis of chest wall tuberculosis has to be based on bacteriologic or histopathological confirmation (2). An initial needle aspiration of the mass is necessary to first establish a diagnosis and second to exclude other diagnoses such as malignancy and other infectious diseases (4). This procedure can show tuberculoid lesion or acid-fast bacilli in direct smear or culture (9,10). But needle aspiration alone is often not reliable, and surgical biopsy is usually required to establish a definite diagnosis (10,12). Needle aspiration, in comparison with surgical exploration, is less invasive and may represent the diagnostic procedure of first choice. In

our series, a definitive diagnosis was made through incisional biopsy. FNA or tru-cut needle biopsy is useful to confirm the presence of tuberculosis or exclude other conditions (7,10). In our patients aspiration and FNA or tru-cut needle biopsy confirmed the diagnosis in only 3 patients. In our series, computed tomography identified rib destruction in only one patient. The combination of a soft tissue mass, osteolytic lesion, and sequestrum in CT-scan of thorax suggests chest wall tuberculosis (11-13). Treatment of chest wall tuberculosis is controversial and there is no consensus on the optimal treatment. Some authors suggest that medical treatment alone is effective (2,14). Others believe that aggressive debridement with primary closure in addition to medical therapy is required to prevent recurrence or formation of a draining sinus (10,14). There are some case series that report good results with anti-tuberculous drugs alone (10-13). But in other series, abscesses were not cured and even recurred or progressed despite adequate medical treatment (7). Our patients responded well to aggressive debridement and medical treatment. However, close follow up is needed in these patients because surgical treatment may ultimately be required (2-7). Faure et al. advised on closing the skin primarily after excision of the abscess, not allowing the formation of a chronic draining sinus (8). In cases with abscess formation, we did not close the skin primarily. We put a small-sized catheter in the cavity and took it out after several days. We believe medical treatment alone is not sufficient and a combination of wide debridement and anti-tuberculous drug regimen is recommended. In a large series of 89 patients with cold abscess of chest wall, excision of chest wall abscess was performed in 28% of cases and excision of both abscess and rib was performed in 72% of cases. Recurrence of the disease was reported in 7.8% of patients. They recommended preoperative and postoperative

tuberculosis medication and complete resection of chest wall mass including any suspicious rib (5). Although WHO recommends a standard 6-month regimen, according to clinical presentation, bacillary load and response to anti-tuberculous medical therapy, the treatment can be extended up to 9–12 months (15). In our patients we used anti-tuberculous medical therapy for 6-9 months.

CONCLUSION

Chest wall tuberculosis mimics symptoms and signs of chest wall tumor or abscess. The combination of symptoms and radiographic findings, suggests the diagnosis of tuberculosis. Wide debridement and resection result in lower incidence of fistula, sinus formation and recurrence. In order to prevent recurrence and fistula formation, medical treatment must be started immediately after surgery.

REFERENCES

- Iseman MD. Extrapulmonary tuberculosis in adults in: Iseman MD. Clinician's guide to tuberculosis. Philadelphia Lippincott. 2000; 145-97.
- Kim YT, Han KN, Kang CH, Sung SW, Kim JH. Complete resection is mandatory for tubercular cold abscess of the chest wall. *Ann Thorac Surg* 2008; 85 (1): 273- 7.
- Newton P, Sharp J, Barnes KL. Bone and Joint tuberculosis in Greater Manchester 1969-79. *Ann Rheum Dis* 1982; 41 (1): 1- 6.
- Kuzucu A, Soysal O, Günen H. The role of surgery in chest wall tuberculosis. *Interact Cardiovasc Thorac Surg* 2004; 3 (1): 99- 103.
- Cho KD, Cho DG, Jo MS, Ahn MI, Park CB. Current surgical therapy for patients with tuberculous abscess of the chest wall. *Ann Thorac Surg* 2006; 81 (4): 1220- 6.
- Sakuraba M, Sagara Y, Komatsu H. Surgical treatment of tuberculous abscess in the chest wall. *Ann Thorac Surg* 2005; 79 (3): 964- 7.
- Davies PD, Humphries MJ, Byfield SP, Nunn AJ, Darbyshire JH, Citron KM, et al. Bone and joint tuberculosis. A survey of notifications in England and Wales. *J Bone Joint Surg Br* 1984; 66 (3): 326- 30.
- Faure E, Souilamas R, Riquet M, Chehab A, Le Pimpec-Barthes F, Manac'h D, et al. Cold abscess of the chest wall: a surgical entity? *Ann Thorac Surg* 1998; 66 (4): 1174- 8.
- Asnis DS, Niegowska A. Tuberculosis of the rib. *Clin Infect Dis* 1997; 24 (5): 1018- 9.
- Hsu HS, Wang LS, Wu YC, Fahn HJ, Huang MH. Management of primary chest wall tuberculosis. *Scand J Thorac Cardiovasc Surg* 1995; 29 (3): 119- 23.
- Ozkara S, Kilicaslan Z, Ozturk F, Seymenoglu S, Erdogan AR, Tellioglu C, et al. Tuberculosis in Turkey with regional data. *Toraks Dergisi* 2002; 3: 178-87.
- Morris BS, Maheshwari M, Chalwa A. Chest wall tuberculosis: a review of CT appearances. *Br J Radiol* 2004; 77 (917): 449- 57.
- Lee G, Im JG, Kim JS, Kang HS, Han MC. Tuberculosis of the ribs: CT appearance. *J Comput Assist Tomogr* 1993; 17 (3): 363- 6.
- Chen CH, Shih JF, Wang LS, Perng RP. Tuberculous subcutaneous abscess: an analysis of seven cases. *Tuber Lung Dis* 1996; 77 (2): 184- 7.
- WHO Stop TB Department. Strategy and framework for effective tuberculosis control. Treatment of tuberculosis: Guidelines for national programs. Geneva: World Health Organization; 2003.