

# Bilateral Lymphoblastic Lymphoma of Breast Mimicking Inflammatory Breast Cancer: A Case Report and Review of Literature

Sharareh Seifi<sup>1</sup>, Zahra Esfahani-Monfared<sup>1</sup>,  
Adnan Khosravi<sup>2</sup>, Naser Kamalian<sup>3</sup>,  
Faezeh Eshaghi<sup>1</sup>, Kian Khodadad<sup>1</sup>

<sup>1</sup> Chronic Respiratory Diseases Research Center, National Research Institute of Tuberculosis and Lung Diseases (NRITLD), Shahid Beheshti University of Medical Sciences, Tehran, Iran, <sup>2</sup> Tobacco Prevention and Control Research Center, NRITLD, Shahid Beheshti University of Medical Sciences, Tehran, Iran, <sup>3</sup> Department of Pathology, Tehran University of Medical Sciences, Tehran, Iran.

We report a 45 year-old woman who had bilateral breast masses with extradural involvement. Pathologic report revealed malignant high-grade lymphoblastic lymphoma. Systemic chemotherapy was performed but 3 months later, lesions indicating relapse in bone and breast re-appeared. She received salvage chemotherapy, but 4 months after that she was expired.

**Key words:** Lymphoma, Breast cancer, Lymphoblastic lymphoma

Received: 4 August 2014

Accepted: 8 November 2014

Correspondence to: Khosravi A

Address: Tobacco Prevention and Control Research Center, NRITLD, Shahid Beheshti University of Medical Sciences, Tehran, Iran.  
Email address: adkhosravi@yahoo.com

## INTRODUCTION

Lymphoblastic neoplasms, which may present as leukemia and/or lymphoma, are divided into two categories (1): Precursor T-cell lymphoblastic leukemia/lymphoma (precursor T-LBL) and Precursor B-cell ALL/LBL. Primary breast involvement with lymphoma (PBL) is very rare (2). It means that less than one percent of all lymphoma cases are PBL (3). PBL clinically, radiologically, and morphologically is similar to both benign and malignant conditions. We report a case of breast lymphoblastic lymphoma and discuss her diagnosis and management. To date, PBL has a poor prognosis; its

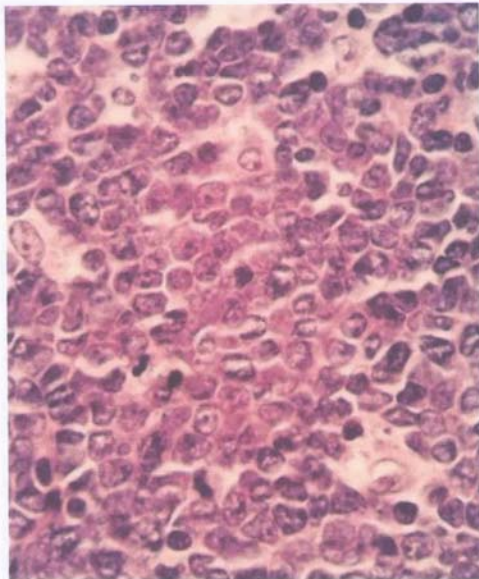
therapeutic strategy is controversial and not completely confirmed.

## CASE SUMMARIES

A 45 year-old woman with 6 months history of low back pain, weight loss, night sweat, fever and galactorrhea was referred to our center. Physical examination revealed multiple and palpable masses in both breasts and galactorrhea without peripheral lymphadenopathy. The rest of physical examination was unremarkable. Ultrasonographic evaluation revealed lobular-shaped, partly ill-defined hypoechoic masses with 2-7 cm

diameters and a multi-septated nodular (mottled) appearance without acoustic changes in both breasts. Mammography showed an extremely dense pattern with bilateral ill-defined, hypodense mass-like lesions. Computer tomographic (CT) scans of the chest and abdomen were normal. CBC and LDH were completely normal. The patient had no contributory past or family history.

Breast lumpectomy was performed in another center and the primary result exhibited malignant non-Hodgkin lymphoma; Malt type and immunohistochemistry (IHC) suggested Maltoma (Figure 1).

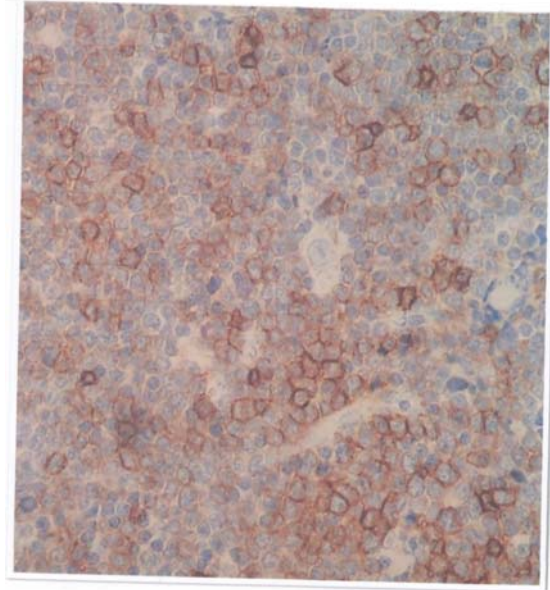


**Figure 1.** Light microscopy of tissue specimen from breast biopsy (hematoxylin and eosin stain; original magnification  $\times 1000$ ).

During the primary work up, her back pain increased and paraplegia occurred. Magnetic resonance imaging (MRI) demonstrated disc protrusion of T8-T9 and spinal surgery was performed immediately. Surgical gross result was extradural soft tissue tumor at T8-T9 with invasion to the bone. Pathologic report revealed malignant high-grade lymphoblastic lymphoma.

She was referred to our department (Medical Oncology and Hematology department of the National Institute of Tuberculosis and Lung disease, NRITLD). First, we suggested reviewing of previous pathology result and

surprisingly it was different suggesting dense lymphoid infiltration with diffuse growing pattern and malignant lymphoblastic lymphoma, B-cell type (CD20, CD3, CD5, CD10, BCL2 were positive in IHC staining) (Figure 2).



**Figure 2.** IHC staining shows positivity for CD20 in neoplastic lymphoid cells.

In the setting of lymphoma staging, bone marrow aspiration and biopsy were performed and bone marrow involvement was highly suspected. Central nervous system involvement was ruled out by lumbar puncture (LP).

The patient was staged IVBE according to the Ann Arbor staging system and International Prognostic Index (IPI) was low-intermediate (4). We started chemotherapy with hyper CVAD regimen (5) (Course 1: [cyclophosphamide: 300mg/m<sup>2</sup>; BID days 1-3; vincristine :2mg/m<sup>2</sup> day 1; doxorubicin: 50mg/m<sup>2</sup> day 4; dexamethasone 40mg/m<sup>2</sup> days 1-4] course 2: [methotrexate: 1000mg/m<sup>2</sup> day 1; cytarabine:3000mg/m<sup>2</sup>BID days 2-3] , with G-CSF support per 2-3 weeks). CNS prophylaxis was done by methotrexate: 12mg day 2 and cytarabine: 100mg day 7. After 4 courses, the patient did not have any complaint and response evaluation with mammography and bone marrow biopsy was completely normal. She was a

candidate for bone marrow transplantation (BMT) due to her stage and IPI but owing to the large number of patients on the waiting list, this process took about 3 months. She developed back pain again and L4/L5 central disc protrusion was seen in MRI. She was admitted to our department. Marked painful swelling of both breasts was detected on physical examination and multiple masses in mammography examination were seen. Chest CT showed minimal pleural effusion in the left side. We treated her by ICE regimen (6) (Ifosfamide 5gr/m<sup>2</sup> for 3 days, Etoposide 100mg/m<sup>2</sup> for 3 days and Carboplatin AUC 5 day 1) for 8 cycles. Unfortunately, she was expired after 4 months.

## DISCUSSION

As first described in 1959(7), breast lymphomas are rare and include 0.04 to 0.5% of all breast malignancies (8). Breast involvement by lymphoma cells can be localized to one or both breasts with or without regional lymph node involvement known as PBL. It can be a part of disseminated disease considered as secondary involvement of the breast. Lymphoepithelial lesions in ducts, lobules and vascular involvement have been seen in breast lymphomas (9). In both primary and secondary breast lymphomas, diffuse large B cell lymphoma (DLBCL) is the most common type (8, 10). Diagnosis is not often delayed due to the similarity of signs with breast cancer (11).

In 1972, Wiseman and Liao (12) defined the criteria for PBL. PBL is a rare diagnosis accounting for 1.7-2.2% of extranodal lymphomas (13). Most cases suffer from advanced stages of the disease and 30-50% of patients have bone marrow involvement (14).

Our patient presented with bilateral breast masses, erythema and edema, which was a very uncommon presentation. Most breast lymphomas present as a painless breast mass located in the upper outer quadrants (15).

LBL is a very rare type of high-grade neoplasm comprising 2-4% of all NHLs (2). Although most cases of LBL have T-cell phenotype (12), the majority of breast NHLs are B-cell phenotype (16). LBL of the breast is an

uncommon diagnosis. Bilateral breast lymphomas are a very rare occurrence. Bilateral breast involvement accounts for 5-11% of all breast lymphomas (17). Some of these patients have poor survival (18).

Some investigators categorize patients into two different groups with respect to their clinicopathological characteristics: the first group includes younger patients with bilateral involvement usually disseminating rapidly to extranodal and extra-mammary sites (7). The second group includes older patients with unilateral involvement (12).

In fact, PBL treatment varies from chemotherapy and/or radiation therapy to surgical procedures (ranging from biopsy to radical mastectomy) and BMT. Some investigators believe that localized tumors have a better prognosis by surgical intervention only. Surgery plus chemotherapy is suggested for systemic involvement (19). Consequently, there is no standard treatment or consensus for PBL (10). Considering the high prevalence of CNS relapse, some clinicians suggest prophylactic CNS therapy (20). Our patient presented with clinical findings suggestive of metastatic carcinoma rather than lymphoma. Careful attention to the concomitant diagnosis of lymphoblastic lymphoma involving other sites helps avoid misdiagnosis of other carcinomas. This case shows the importance of performing a careful and thorough clinical and pathological evaluation when considering a diagnosis of a rare lymphoma subtype involving the breast.

## CONCLUSION

This case highlights the atypical presentation of lymphoma mimicking an inflammatory breast cancer or other neoplasms presenting as bilateral breast masses. Core biopsy of the breast lesion will be helpful, and BMT is strongly recommended due to poor prognosis. Finally, we believe that the approach to breast lymphoma should be similar to that of the equivalent types presenting elsewhere.

## Acknowledgement

The authors wish to thank the patient's family and the National Institute of Tuberculosis and Lung Disease, Masih Daneshvari Hospital.

## REFERENCES

1. Swerdlow SH, Campo E, Harris NL, et al. WHO Classification of Tumours of Haematopoietic and Lymphoid Tissues. Lyon, France: IARC Press; 2008.
2. Bayrak IK, Yalin T, Ozmen Z, Aksoz T, Doughanji R. Acute lymphoblastic leukemia presented as multiple breast masses. *Korean J Radiol* 2009; 10 (5): 508- 10.
3. Topalovski M, Crisan D, Mattson JC. Lymphoma of the breast. A clinicopathologic study of primary and secondary cases. *Arch Pathol Lab Med* 1999; 123 (12): 1208- 18.
4. Morris K, Weston H, Mollee P, Marlton P, Gill D, et al. Outcome of treatment of adult acute lymphoblastic leukemia with hyperfractionated cyclophosphamide, doxorubicin, vincristine, dexamethasone/methotrexate, cytarabine: results from an Australian population. *Leuk Lymphoma* 2011; 52 (1): 85- 91.
5. A predictive model for aggressive non-Hodgkin's lymphoma. The International Non-Hodgkin's Lymphoma Prognostic Factors Project. *N Engl J Med* 1993; 329 (14): 987- 94.
6. Gisselbrecht C, Glass B, Mounier N, Singh Gill D, Linch DC, Trneny M, et al. Salvage regimens with autologous transplantation for relapsed large B-cell lymphoma in the rituximab era. *J Clin Oncol* 2010; 28 (27): 4184- 90.
7. Dobrotina AF, Zlotnikova ZB. Generalized sarcomatosis (lymphosarcomatosis) in pregnancy with unusual with unusual bilateral involvement of the breasts. *Vopr Onkol* 1959; 5 (5): 613- 6.
8. Joks M, Myśliwiec K, Lewandowski K. Primary breast lymphoma - a review of the literature and report of three cases. *Arch Med Sci* 2011; 7 (1): 27- 33.
9. Baker R<sup>1</sup>, Slayden G, Jennings W. Multifocal primary breast lymphoma. *South Med J* 2005; 98 (10): 1045- 8.
10. Gholam D<sup>1</sup>, Bibeau F, El Weshi A, Bosq J, Ribrag V. Primary breast lymphoma. *Leuk Lymphoma* 2003; 44 (7): 1173- 8.
11. Validire P, Capovilla M, Asselain B, Kirova Y, Goudefroye R, Plancher C, et al. Primary breast non-Hodgkin's lymphoma: a large single center study of initial characteristics, natural history, and prognostic factors. *Am J Hematol* 2009; 84 (3): 133- 9.
12. Wiseman C, Liao KT. Primary lymphoma of the breast. *Cancer* 1972; 29 (6): 1705- 12.
13. Park YH, Kim SH, Choi SJ, Ryoo BY, Kang YK, Lee SS. Primary malignant lymphoma of the breast: clinicopathological study of nine cases. *Leuk Lymphoma* 2004; 45 (2): 327- 30.
14. Thomas DA, Kantarjian HM. Lymphoblastic lymphoma. *Hematol Oncol Clin North Am* 2001; 15 (1): 51- 95, vi.
15. Garg NK, Bagul NB, Rubin G, Shah EF. Primary lymphoma of the breast involving both axillae with bilateral breast carcinoma. *World J Surg Oncol* 2008; 6: 52.
16. Vianello F, Sgarabotto D, Stefani PM, Radossi P, Sartori R, Sartori D, et al. Primary breast lymphoma. *Forum (Genova)* 1998; 8 (2): 188- 95.
17. Yang H, Lang RG, Liu FF, Wang XF, Jin ZJ, Lü AJ, et al. Primary lymphoma of breast: a clinicopathologic and prognostic study of 40 cases. *Zhonghua Bing Li Xue Za Zhi* 2011; 40 (2): 79- 84.
18. Baltzer J, Zander J, Holzgreve H, Löhrs U, Bach HG, Heilmann K. Bilateral malignant lymphoblastic lymphoma of the female breast (author's transl). *Dtsch Med Wochenschr* 1978; 103 (5): 211- 5.
19. Hasegawa S, Kosaka A, Mori I. A case of primary malignant lymphoma of the breast. *Nippon Rinsyo Geka Igakukai Zasshi* 1995; 56: 519- 23.
20. Avilés A, Delgado S, Nambo MJ, Neri N, Murillo E, Cleto S. Primary breast lymphoma: results of a controlled clinical trial. *Oncology* 2005; 69 (3): 256- 60.