

Pulmonary Paecilomyces in a Diabetic Patient

Sara Abolghasemi ¹, Payam Tabarsi ²,
Parvaneh Adimi ³, Arda Kiani ⁴, Samaneh
Dolatshahi ¹, Davood Mansouri ²

¹ Department of Internal Medicine, Division of Infectious Disease and Clinical Immunology, National Research Institute of Tuberculosis and Lung Disease (NRITLD), Shahid Beheshti University of Medical Sciences, Tehran, Iran, ² Clinical Tuberculosis and Epidemiology Research Center, NRITLD, Shahid Beheshti University of Medical Sciences, Tehran, Iran, ³ Department of Medical Mycology and Parasitology, Islamic Azad University, Tehran Medical Branch, Tehran, Iran, ⁴ Tracheal Diseases Research Center, NRITLD, Shahid Beheshti University of Medical Sciences, Tehran, Iran

Received: 16 April 2015

Accepted: 22 June 2015

Correspondence to: Mansouri D

Address: Clinical Tuberculosis and Epidemiology Research Center, NRITLD, Shahid Beheshti University of Medical Sciences, Tehran, Iran.

Email address: dmansouree@yahoo.com

INTRODUCTION

Immunosuppressive drug advancement and the emergence of human immunodeficiency virus have dramatically increased the incidence of mycosis and this has expanded the range of fungi causing potentially fatal diseases (1).

Paecilomyces species, which are among the most frequently found saprophytes in the environment (2) have been isolated from foods, soil, indoor air and wood. Although these infections are not common, they are among the emerging causes of opportunistic infections in immunocompromised hosts (3). Two species namely *Paecilomyces lilacinus* and *P. variotii* are the most frequently isolated species from humans (4).

Paecilomyces species are among the most frequent saprophytes. Two species namely *Paecilomyces lilacinus* and *Paecilomyces variotii* are the most frequently isolated species from humans. Fungemia, endocarditis peritonitis, osteomyelitis and rarely pneumonia have been reported.

We report a 74-year old diabetic woman with *Paecilomyces variotii* pneumonia. *Paecilomyces variotii* is a rare cause of pneumonia and in our knowledge, our case is the first case of pleural effusion due to this fungus.

Key words: *Paecilomyces variotii*; Diabetic patient; Pleural effusion

Many types of infections such as fungemia, endocarditis, peritonitis, osteomyelitis and rarely pneumonia have been reported (5).

Some risk factors for Paecilomyces include invasive diseases such as neutropenia, depressed cellular immunity, corticosteroid use, diabetes mellitus, and transplantation(6). We describe a diabetic woman with pneumonia and pleural effusion due to *Paecilomyces variotii*.

CASE SUMMARY

A 74-year-old Iranian woman presented with a 10-day history of malaise, weakness, fever, chills and sweating with no weight loss. She had received oral antibiotics four days after initial symptoms but did not improve.

She had travelled to Thailand about one month earlier and stayed there for three weeks. She reported swimming in the sea there. After returning, she had an 8-day travel to south of Iran, Ahwaz. Few days after coming back to Tehran, her symptoms began. She was a housewife and non-smoker and was diabetic from one year ago, hypertensive for many years and had hypothyroidism in the past eight years. She reported two Cesarean section surgeries and cholecystectomy many years ago. Her medications included glibenclamide, atenolol and levothyroxine. She had no history of blood transfusion, asthma or allergy.

The patient had been admitted to another hospital first where chest X ray was performed and bilateral pleural effusion was observed; pleural tapping was performed and the result showed exudative neutrophilic pleural effusion. She had WBC count of about 2,500/mL (PMN=60%, lymph= 40%), LDH was 240 IU/L, protein and glucose were 4.2g/dL and 74 mg/dL, respectively. Simultaneous serum LDH and protein were 300 IU/L and 5g/dL, respectively. She had received intravenous antibiotics for five days due to the impression of pneumonia but did not improve. Then, she was admitted to our hospital; she was febrile and reported non-productive cough and dyspnea, malaise and sweating. Complete blood count showed only anemia (Hb =9) without any leukocytosis or leukopenia. The erythrocyte sedimentation rate was 120mm/h and C-reactive protein was 68mg/L. Biochemistry tests, electrolyte levels and thyroid function tests were normal. Tuberculin skin test was negative and angiotensin-converting enzyme level was 63 μ /L (normal range is up to 65 μ /L)

High-resolution chest computed tomography (CT) scan was requested, which showed bilateral pleural effusion again (Figure 1). There was no evidence of pulmonary emboli in chest CT angiography scan and echocardiography. Her echocardiography showed mild pericardial effusion with possible pericardial thickness. At this time, pleural tapping indicated lymphocytic exudative pleural effusion; the WBC count was 750/mL (PMN=40%, lymph=60%). Adenosine deaminase (ADA) was normal

and smear was negative for Acid-fast bacilli and other bacteria. *Mycobacterium tuberculosis* polymerase chain reaction was negative. Meropenem and ciprofloxacin were initiated but the patient did not improve and worsened.

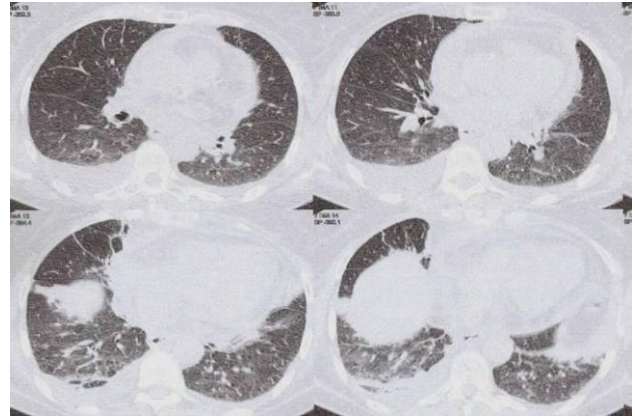


Figure 1. Chest CTscan showing bilateral pleural effusion

Paecilomyces variotii was isolated from fungal culture of pleural effusion in several plates. Colonies grew on Sabouraud dextrose agar and reached about 7-8 mm after one week. The fungus was recognized based on its colony morphology, microscopic structures and thermophilicity (Figure 2). Thus, the patient was started on Itraconazole 200mg twice daily. After 48 hours, the patient became afebrile and the symptoms improved. She was evaluated for immunodeficiency. Immunoglobulin levels were normal, rheumatologic evaluation and tumor markers were unremarkable and NBT test was 100%.

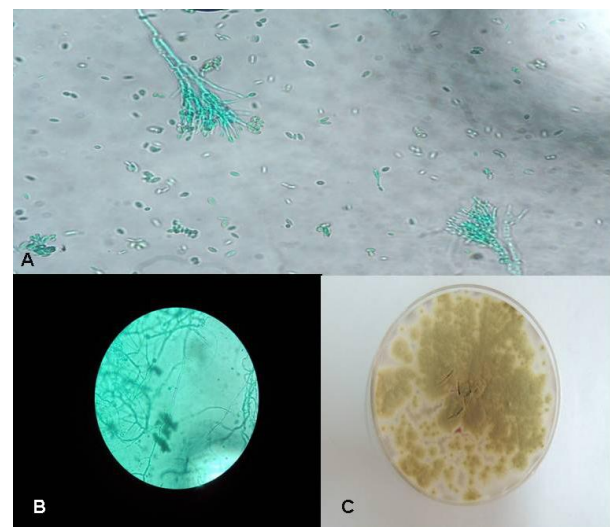


Figure 2. Branched conidiophores and cylindrical conidiogenous cells with tapering tips;lacto-phenol stain(A,B), Yellow -brown colonies of *Paecilomyces Variotii* (C)

We continued treatment with itraconazole for four weeks. After four weeks, the patient had good general condition without any sign or symptom, erythrocyte sedimentation rate was 70mm/h, hemoglobin was 10.8mg/dL and her new chest X ray was clear (Figure 3).

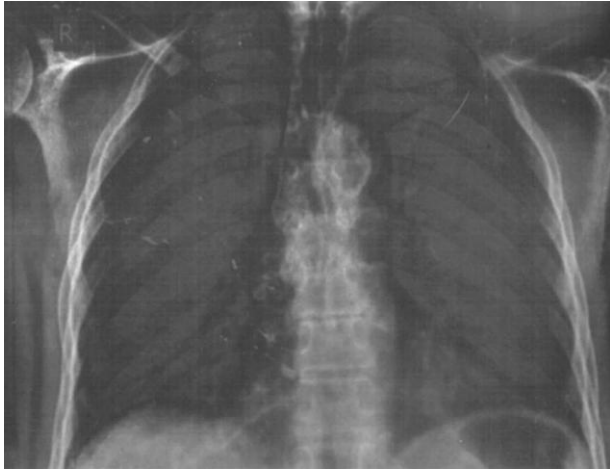


Figure 3. Normal chest X ray of patient four weeks after treatment.

DISCUSSION

Paecilomyces is a globally distributed filamentous fungus, which exists in the soil, decaying plants and food products. *Paecilomyces* is also found as an airborne contaminant in greenhouses, sawmills, and water damaged houses (7). It can be isolated from *Penicillium* by its loosely branched conidiophores and cylindrical conidiogenous cells with tapering tips (5). The color of the colony and certain microscopic features can help differentiate the most common two species namely *Paecilomyces lilacinus* and *Paecilomyces variotii* from each other. Another factor that helps in differentiation is thermophilicity of *Paecilomyces variotii*, since it can grow well at temperatures as high as 50 or possibly 60°C(8).

Pulmonary infection due to *P. variotii* has been reported in five patients (5, 8- 11). The fungi were found in the sputum or bronchoalveolar lavage in all cases, but we isolated *P. variotii* from the pleural fluid of the patient and this site of isolation has not been previously reported. Pleural effusion caused by *Paecilomyces lilacinus* has been reported previously in Malta (12) and also *Paecilomyces*

lilacinus has been recognized as a cause of rhinitis and allergic alveolitis in individuals living in substandard urban places in the vicinity of decaying woods (13). Some studies have indicated *P. variotii* as an aeroallergen and occupational hazard (14). Our patient had two recent travels to Thailand and south of Iran; the latter has tropical climate with dusty air, but we do not have any information about the existence of *Paecilomyces variotii* in soil in south of Iran. Thailand generally has hot and humid weather and there are a range of fungal infections that are common in this climate. Many cases of penicilliosis have been reported in southeast Asia particularly in AIDS patients in the northern Thailand; moreover the disease continues to be a problem among the returning travelers (15). None of the *Paecilomyces pneumonia* reported cases have ever been in Thailand (5,7,9-11). But we know for a fact that *Paecilomyces variotii* is a worldwide saprophyte so it can be in the dust haze of Ahwaz or in the soil of Thailand and we know its significant role in causing hypersensitivity pneumonitis (16).

The optimal treatment for *Paecilomyces* species has not been established and treatment failure is frequently reported (17).

Treatment of *P. lilacinus* may be more difficult (3), which has poor susceptibility to amphotericin B, itraconazole and echinocandins but *Paecilomyces variotii* is susceptible to many antifungal agents except for voriconazole and ravuconazole (5). There is little experience about the usage of Itraconazole against *Paecilomyces* spp. infections, but on the basis of its good *in vitro* response to *P. variotii* we may be able to use this drug in patients with severe infection (18). Our patient was treated with itraconazole and continued to respond well to therapy and did not show any adverse effect. However, the correlation between the *in vitro* and *in vivo* activity of the drugs against *Paecilomyces* species should be investigated.

CONCLUSION

Paecilomyces variotii is a rare cause of pneumonia and our case was the first case of pleural effusion due to this

fungus; but studies have shown its role as an aeroallergen causing hypersensitivity pneumonitis. Therefore, with the dust haze in the south of Iran and some other countries we expect to see more fungal pneumonitis or allergic alveolitis cases by *Paecilomyces* and other saprophytic fungi in the future.

REFERENCES

- Mandell GL, Bennett JE, Dolin R. Principles and practices of infectious diseases. In: Bennett JE, Introduction to mycosis . 8th ed. New York: Livingstone;2015. p.2873-2878.
- Williamson PR, Kwon-Chung KJ, Gallin JI. Successful treatment of *Paecilomyces variotii* infection in a patient with chronic granulomatous disease and a review of *Paecilomyces* species infections. *Clin Infect Dis* 1992; 14 (5): 1023- 61.
- Houbraken J, Verweij PE, Rijs AJ, Borman AM, Samson RA. Identification of *Paecilomyces variotii* in clinical samples and settings. *J Clin Microbiol* 2010; 48 (8): 2754- 61.
- Walsh TJ, Groll A, Hiemenz J, Fleming R, Roilides E, Anaissie E. Infections due to emerging and uncommon medically important fungal pathogens. *Clin Microbiol Infect* 2004; 10 Suppl 1: 48-66.
- Steiner B, Aquino VR, Paz AA, Silla LM, Zavascki A, Goldani LZ. *Paecilomyces variotii* as an Emergent Pathogenic Agent of Pneumonia. *Case Rep Infect Dis* 2013; 2013: 273848.
- Gutiérrez-Rodero F, Moragón M, Ortiz de la Tabla V, Mayol MJ, Martín C. Cutaneous hyalohyphomycosis caused by *Paecilomyces lilacinus* in an immunocompetent host successfully treated with itraconazole: case report and review. *Eur J Clin Microbiol Infect Dis* 1999; 18 (11): 814- 8.
- Grossman CE. *Paecilomyces*: emerging fungal pathogen. *Chest* 2005; 128 (4_MeetingAbstracts): 425S-.
- Abbas SQ, Maan A, Iqbal J, Niaz M, Waqas M, Ahmed H, et al. A report of *Paecilomyces variotii* on human from Pakistan. *Pakistan Journal of Botany* 2009; 41: 467- 72.
- Saddad N, Shigemitsu H, Christianson A. Pneumonia from *Paecilomyces* in a 67-year-old immunocompetent man. *Chest* 2007; 132 (4_MeetingAbstracts): 710-.
- Byrd RP Jr, Roy TM, Fields CL, Lynch JA. *Paecilomyces variotii* pneumonia in a patient with diabetes mellitus. *J Diabetes Complications* 1992; 6(2): 150- 3.
- Dharmasena FM, Davies GS, Catovsky D. *Paecilomyces variotii* pneumonia complicating hairy cell leukaemia. *Br Med J (Clin Res Ed)* 1985; 290 (6473): 967- 8.
- Fenech FF, Mallia CP. Pleural effusion caused by *Penicillium lilacinum*. *Br J Dis Chest* 1972; 66 (4): 284- 90.
- Ciecko SC¹, Scher R. Invasive fungal rhinitis caused by *Paecilomyces lilacinus* infection: Report of a case and a novel treatment. *Ear Nose Throat J* 2010; 89 (12): 594- 5.
- Green BJ, Rittenour WR, Hettick JM, Janotka E, Beezhold DH. Characterization of *Paecilomyces variotii* Allergens. *Journal of Allergy and Clinical Immunology* 2011; 127 (2): AB264.
- Dearry AD, Collman GW, Saint C, Fields N, Redd S. Building a network of research in children's environmental health. *Environ Health Perspect* 1999; 107(Suppl 3):391.
- Panackal AA, Hajjeh RA, Cetron MS, Warnock DW. Fungal infections among returning travelers. *Clin Infect Dis* 2002; 35(9): 1088-95.
- Martin CA, Roberts S, Greenberg RN. Voriconazole treatment of disseminated *Paecilomyces* infection in a patient with acquired immunodeficiency syndrome. *Clinical Infectious Diseases* 2002; 35(7): e78-81.
- Aguilar C, Pujol I, Sala J, Guarro J. Antifungal susceptibilities of *Paecilomyces* species. *Antimicrob Agents Chemother* 1998; 42(7): 1601-4.